

Pelvic Ring Injuries:

Early and Definitive Management



Alvin Shieh, M.D.



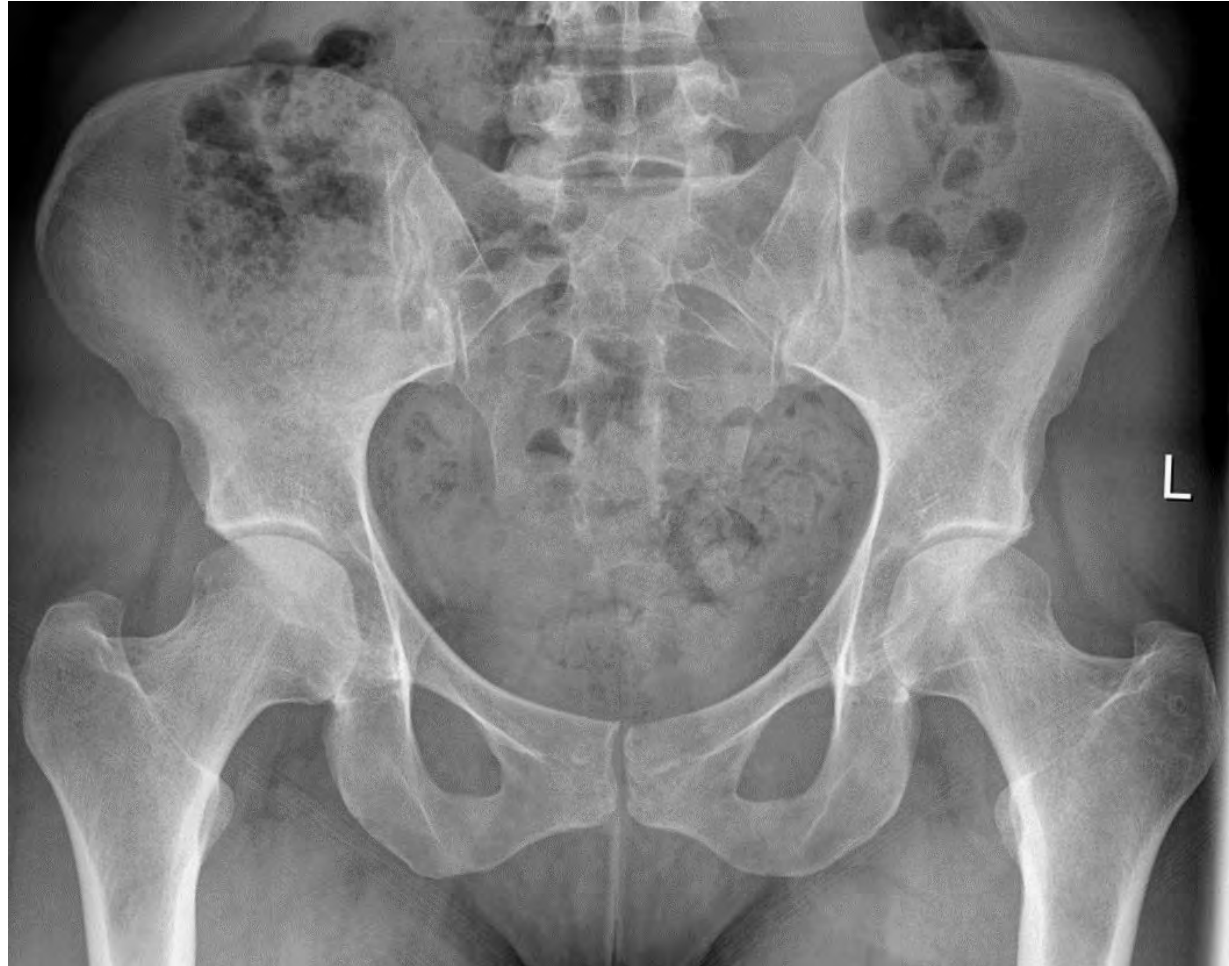Disclosures

- None



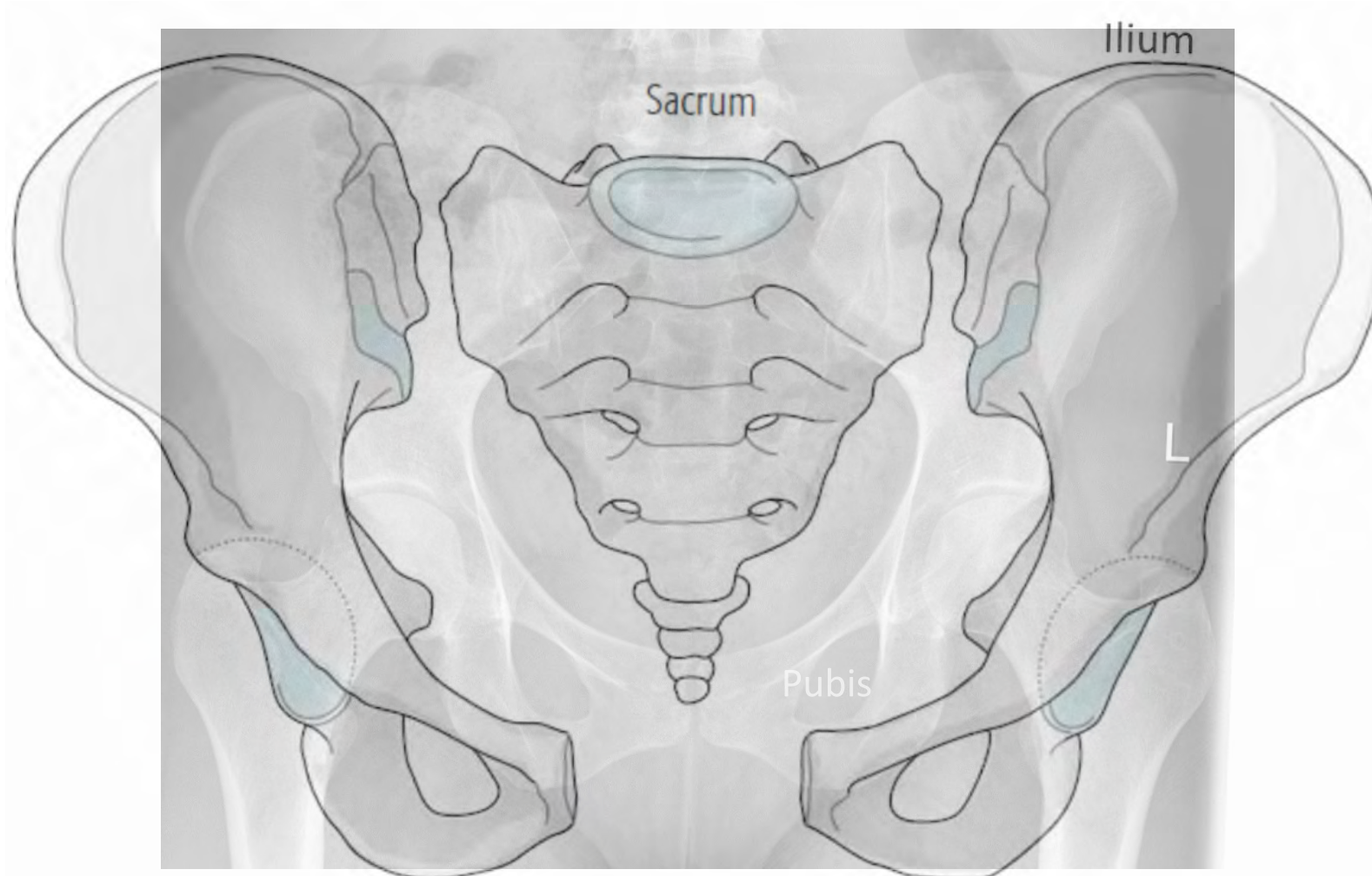


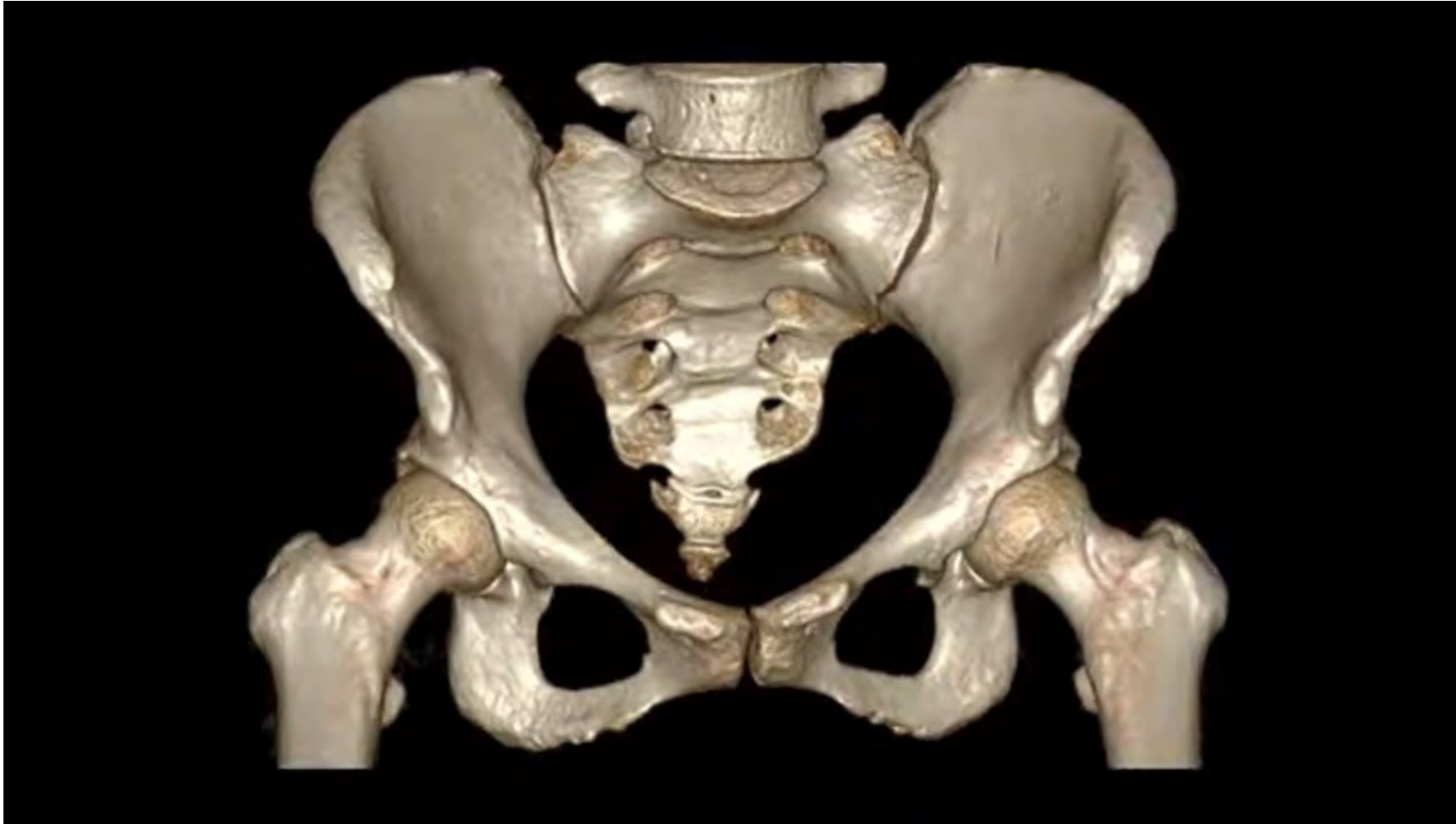Normal





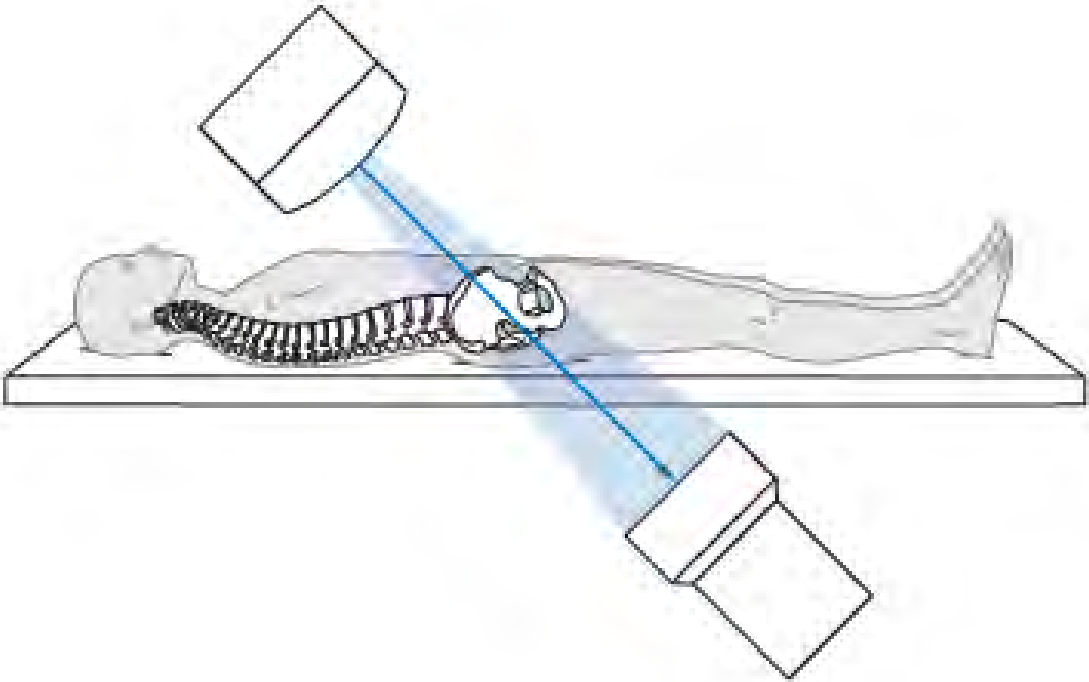
Bones





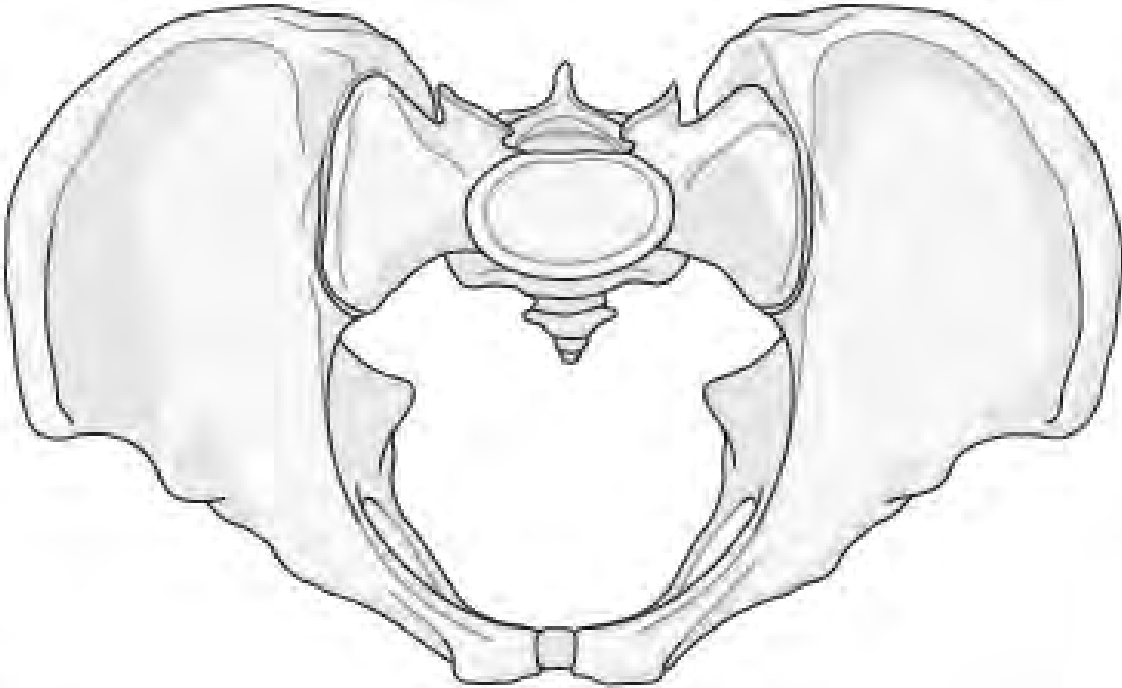


Inlet View



b

Posterior

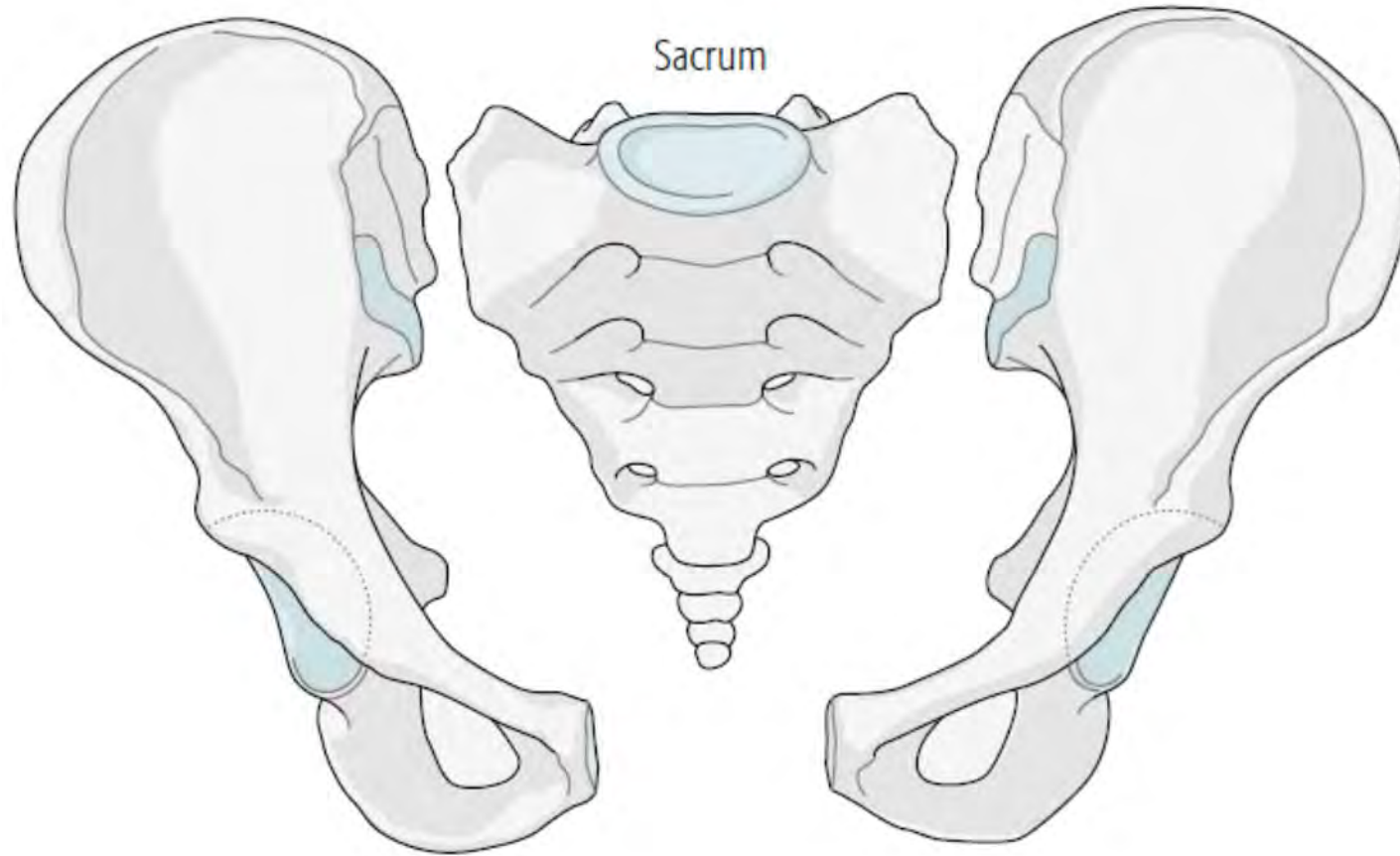


Anterior



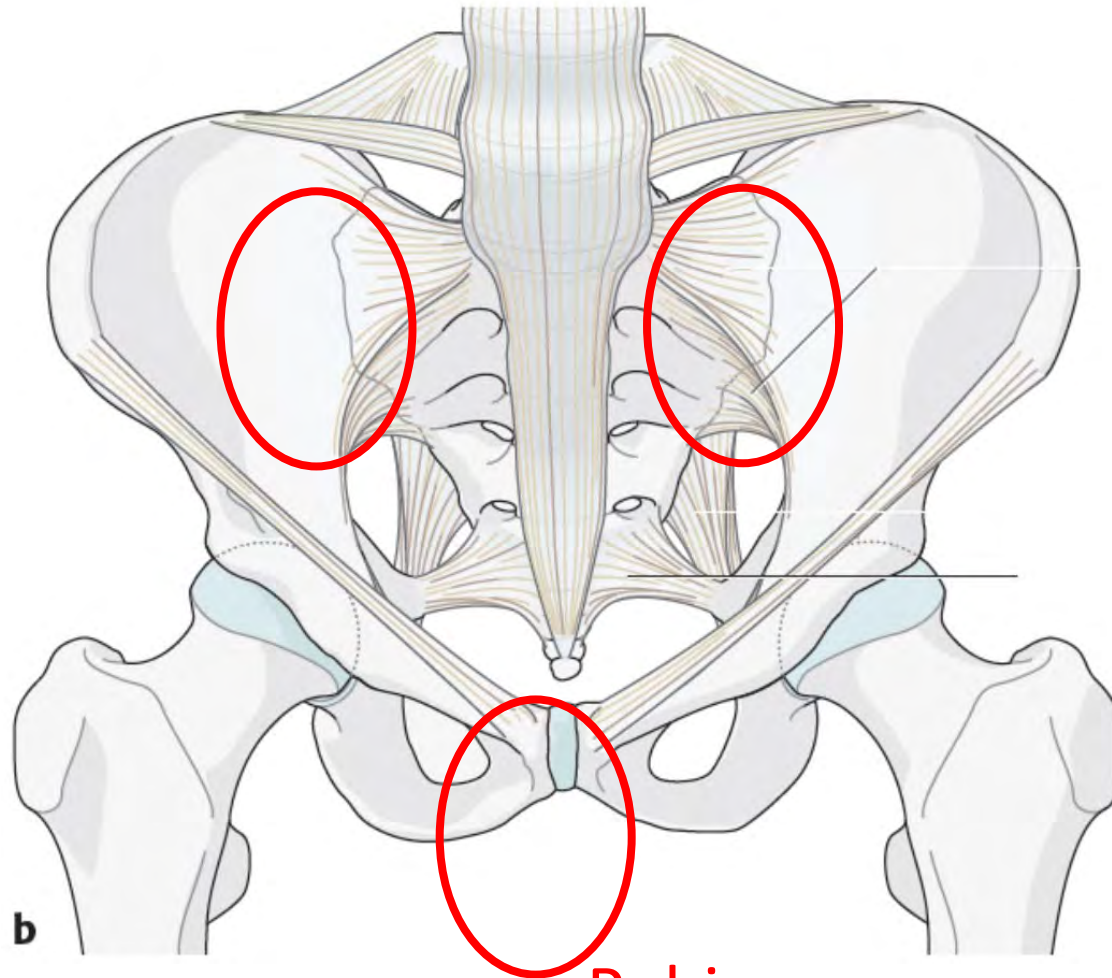


Posterior



Anterior

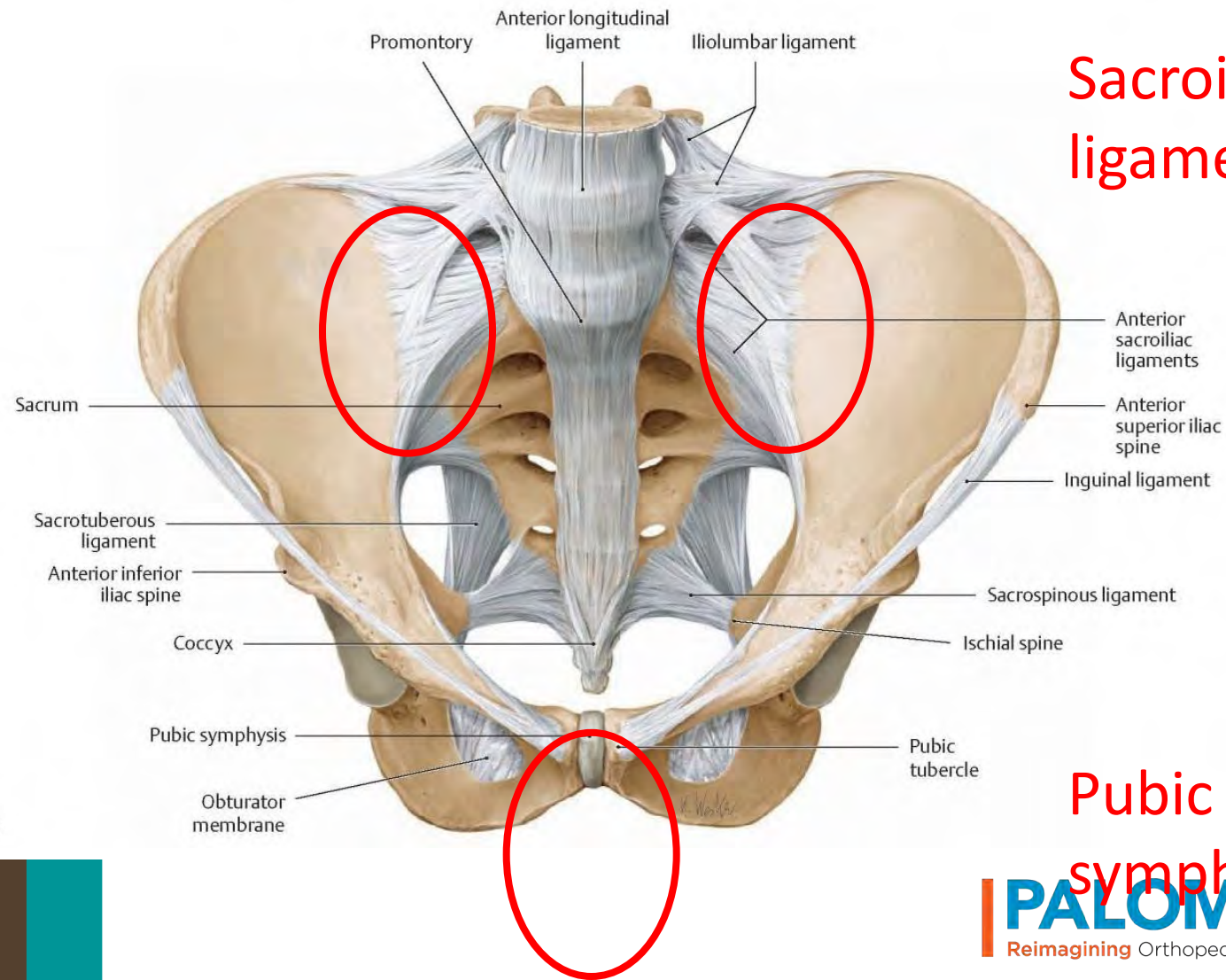




Sacroiliac
ligaments

Pubic
symphysis

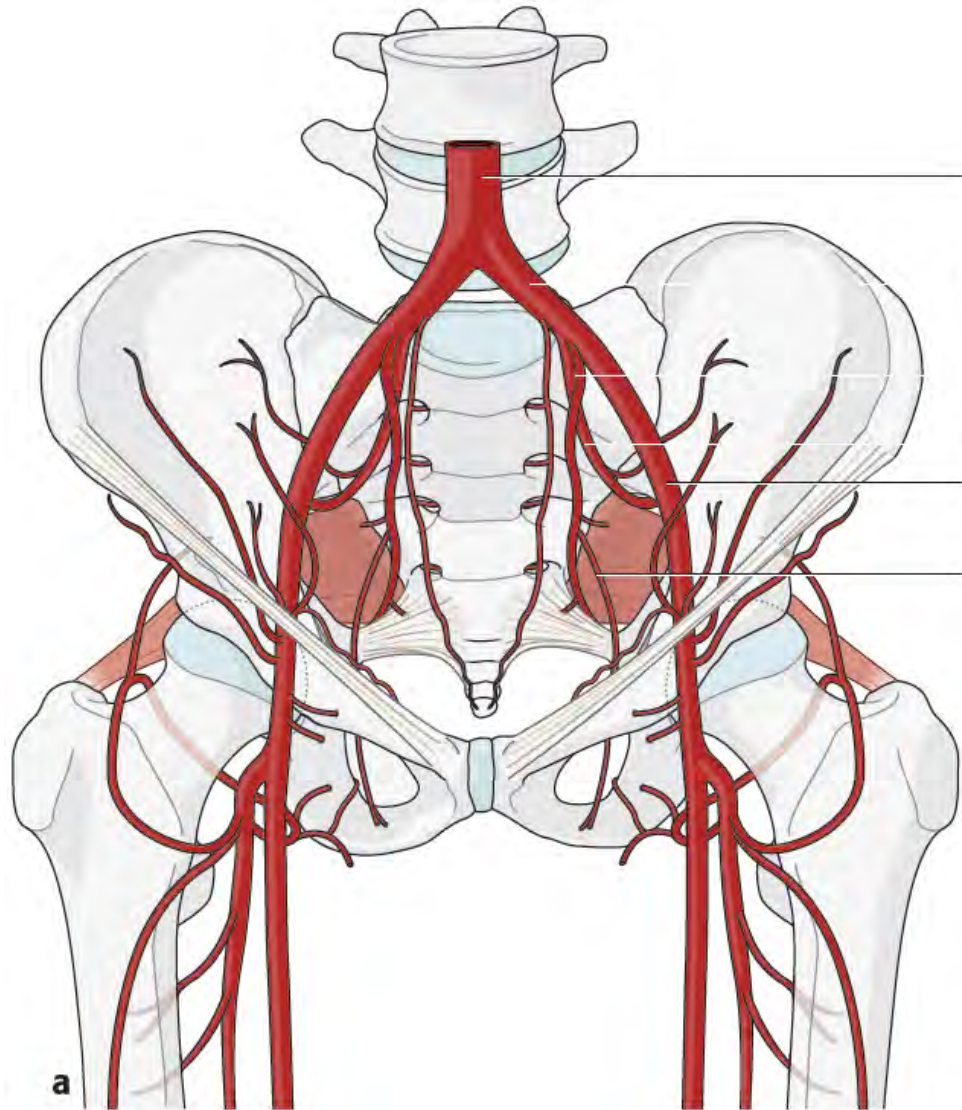




Sacroiliac ligaments

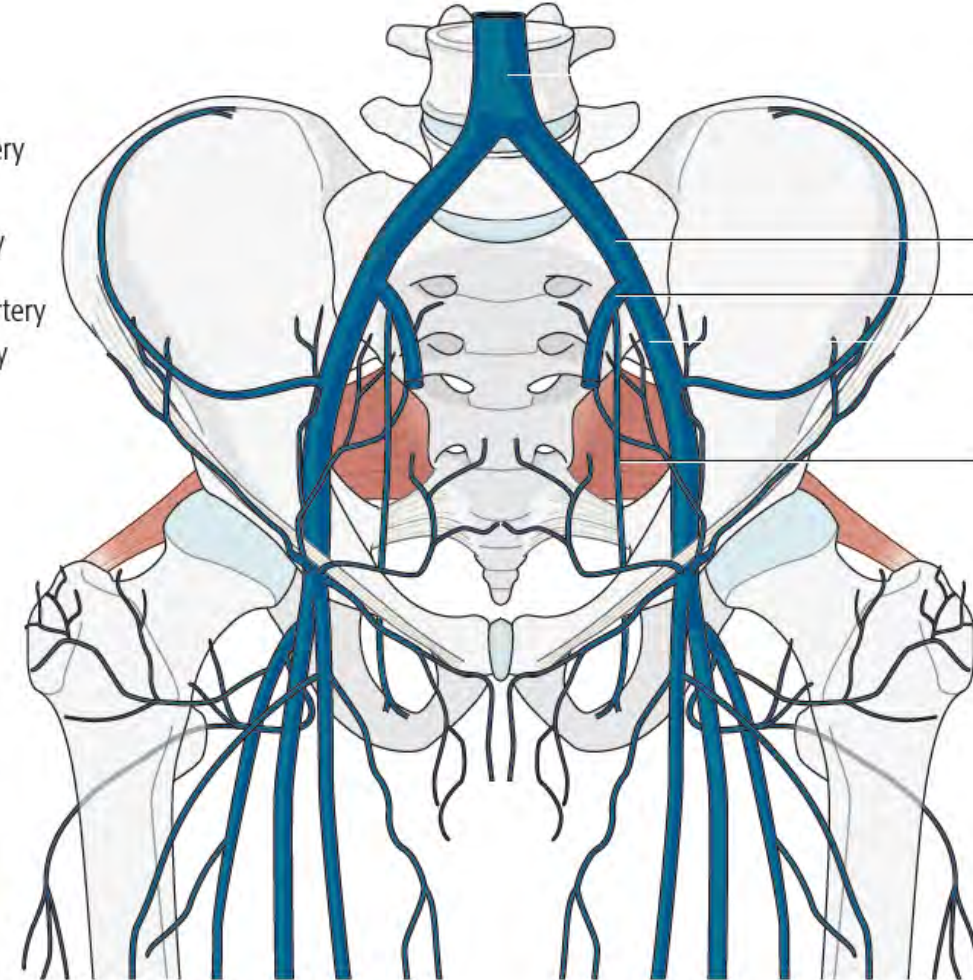
Pubic symphysis





- Aorta
- Common iliac artery
- Internal iliac artery
- Superior gluteal artery
- External iliac artery
- Obturator artery

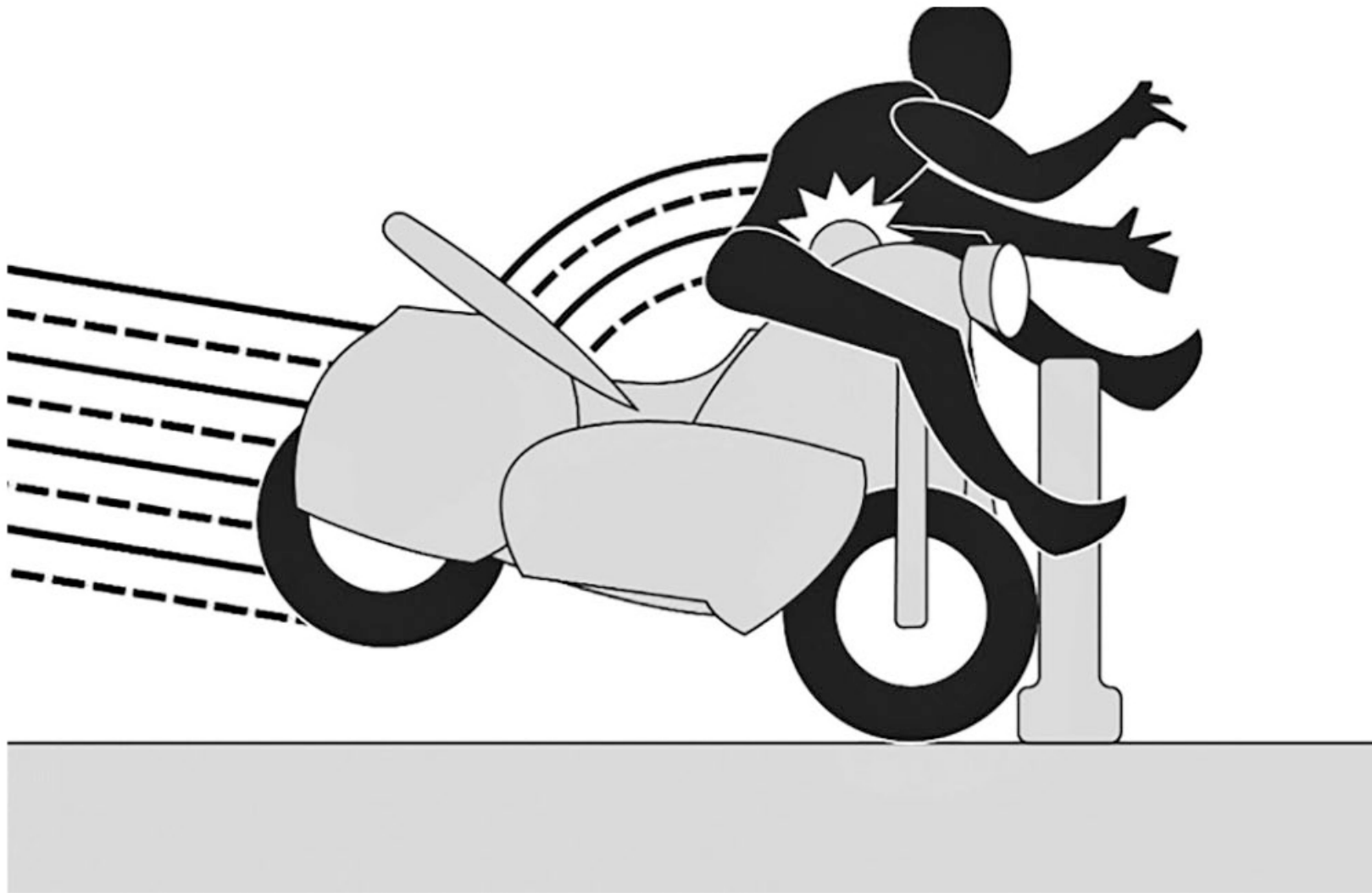
a

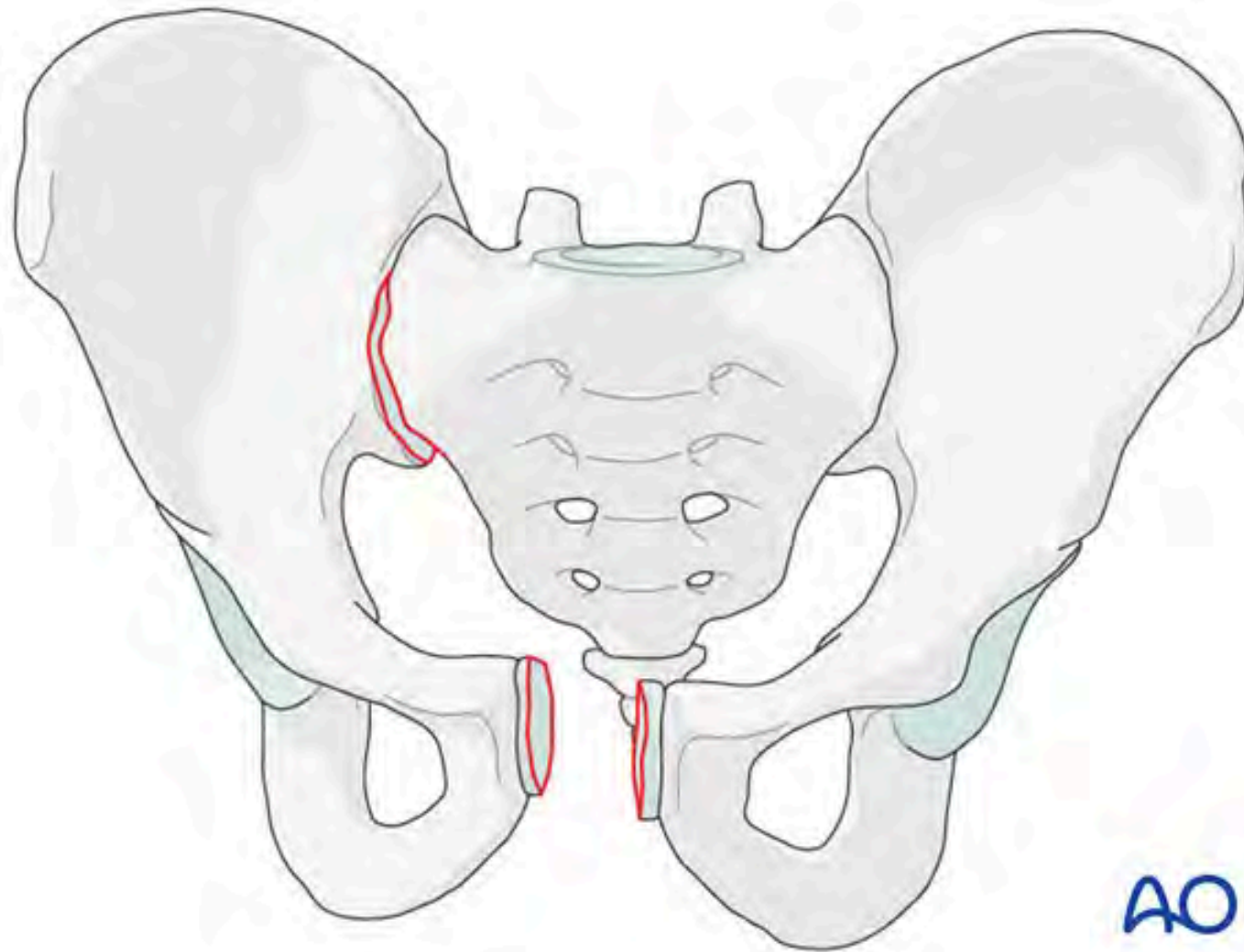


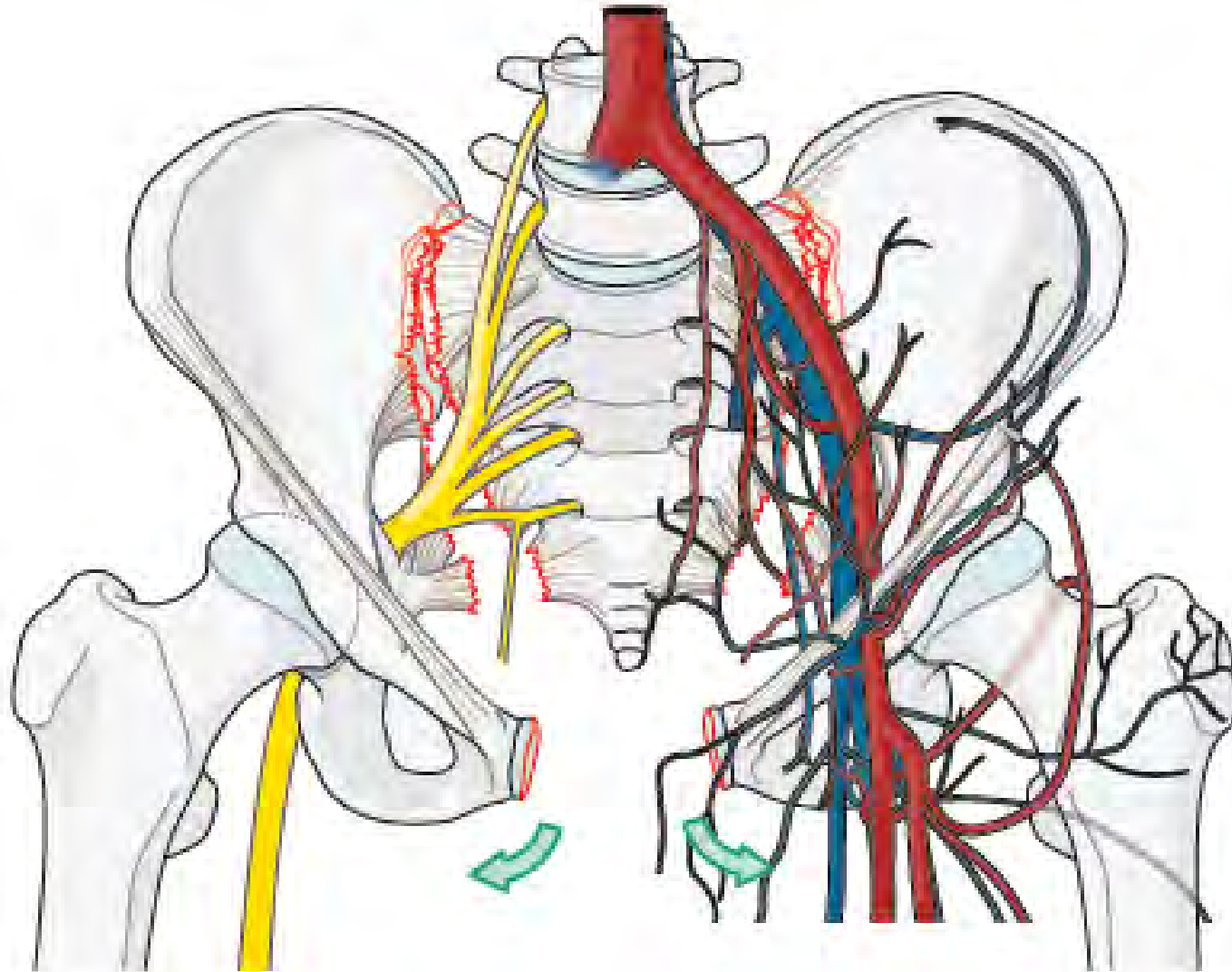
- Inferior vena cava
- Common iliac vein
- Internal iliac vein
- External iliac vein
- Obturator vein

b





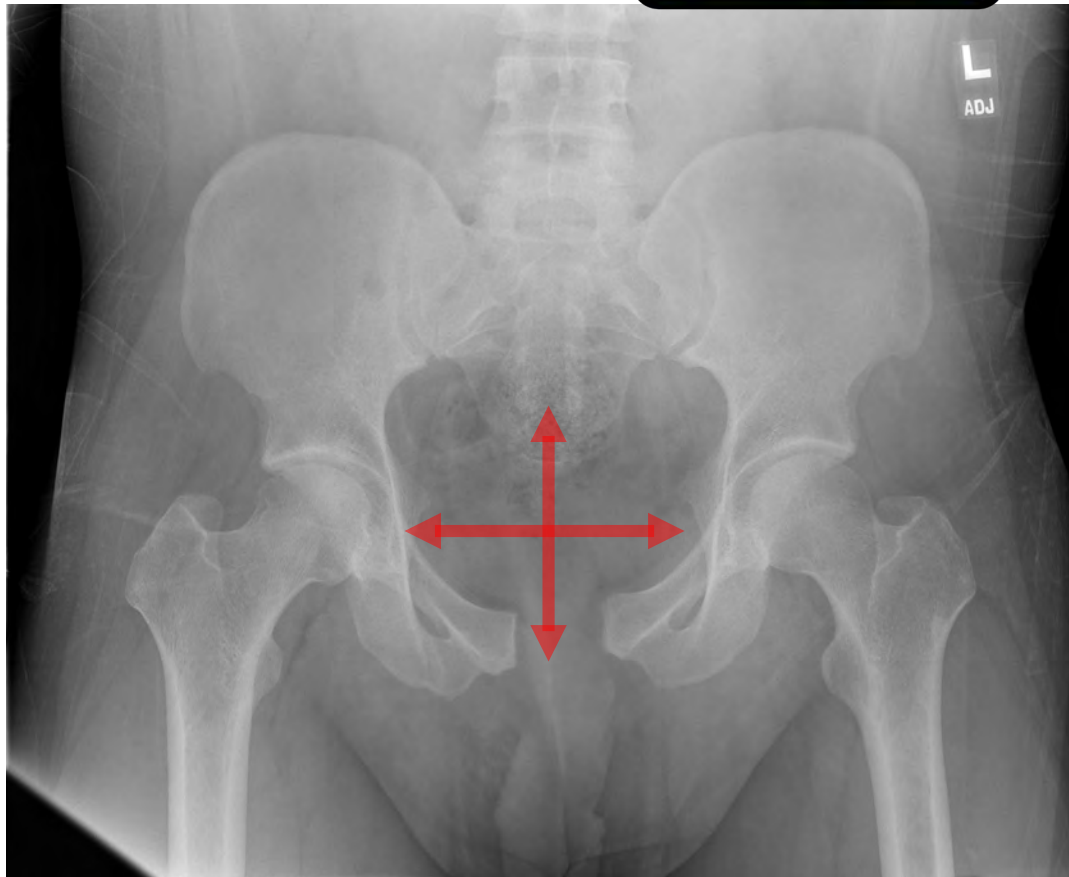




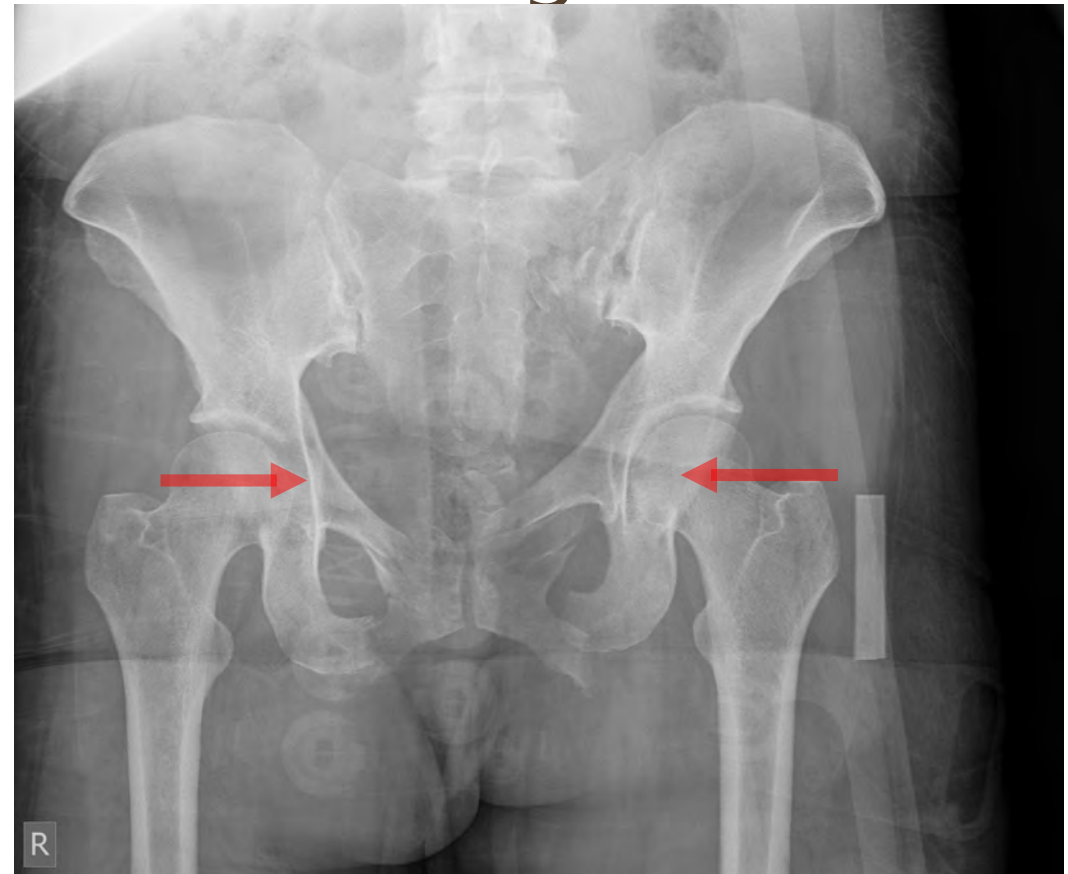


Volume

Expanding



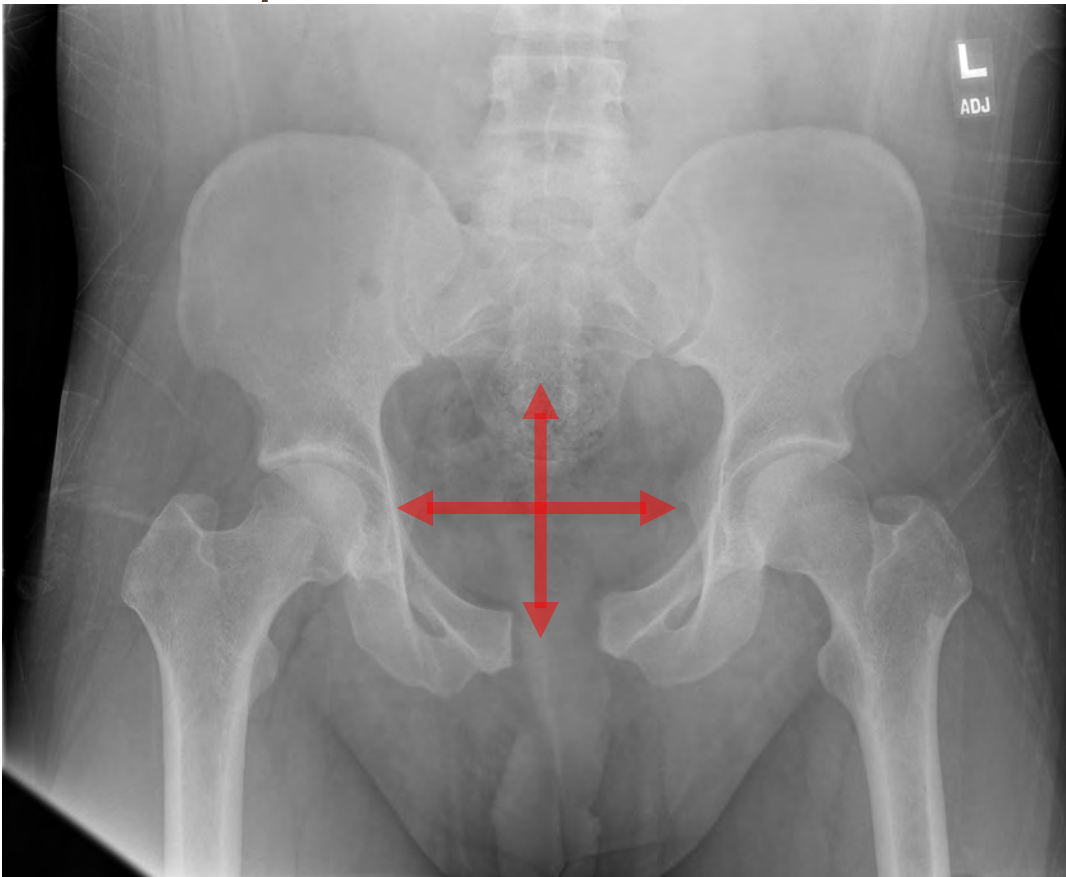
Decreasing



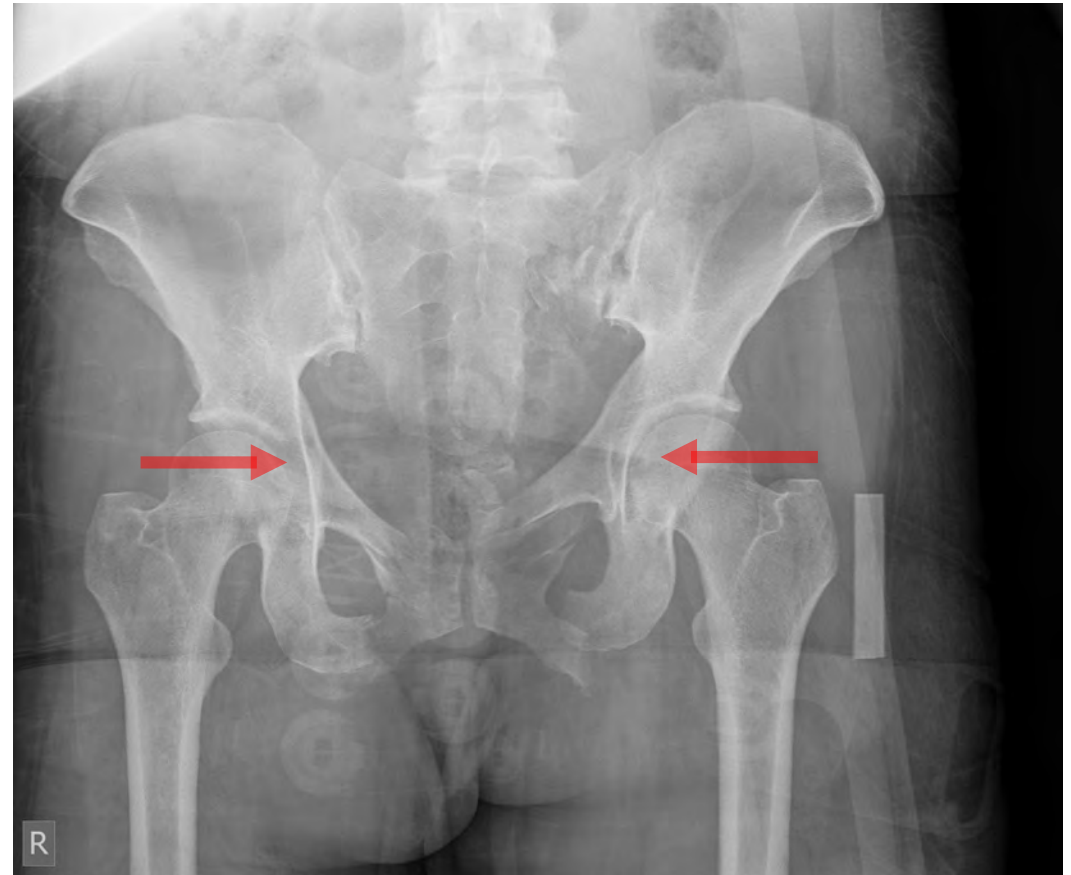


Mechanism

Anterior-posterior
Compression (APC)

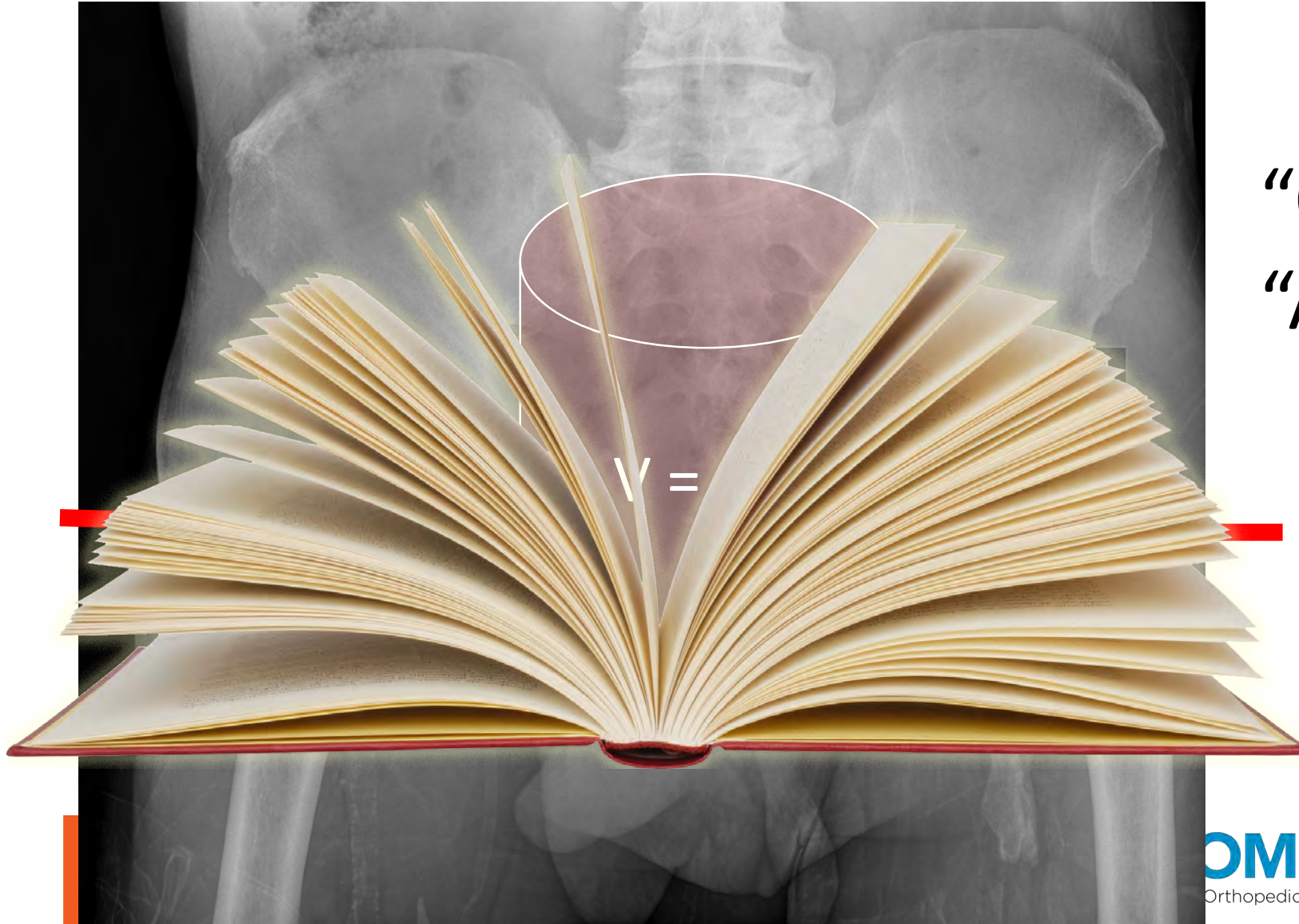


Lateral Compression (LC)





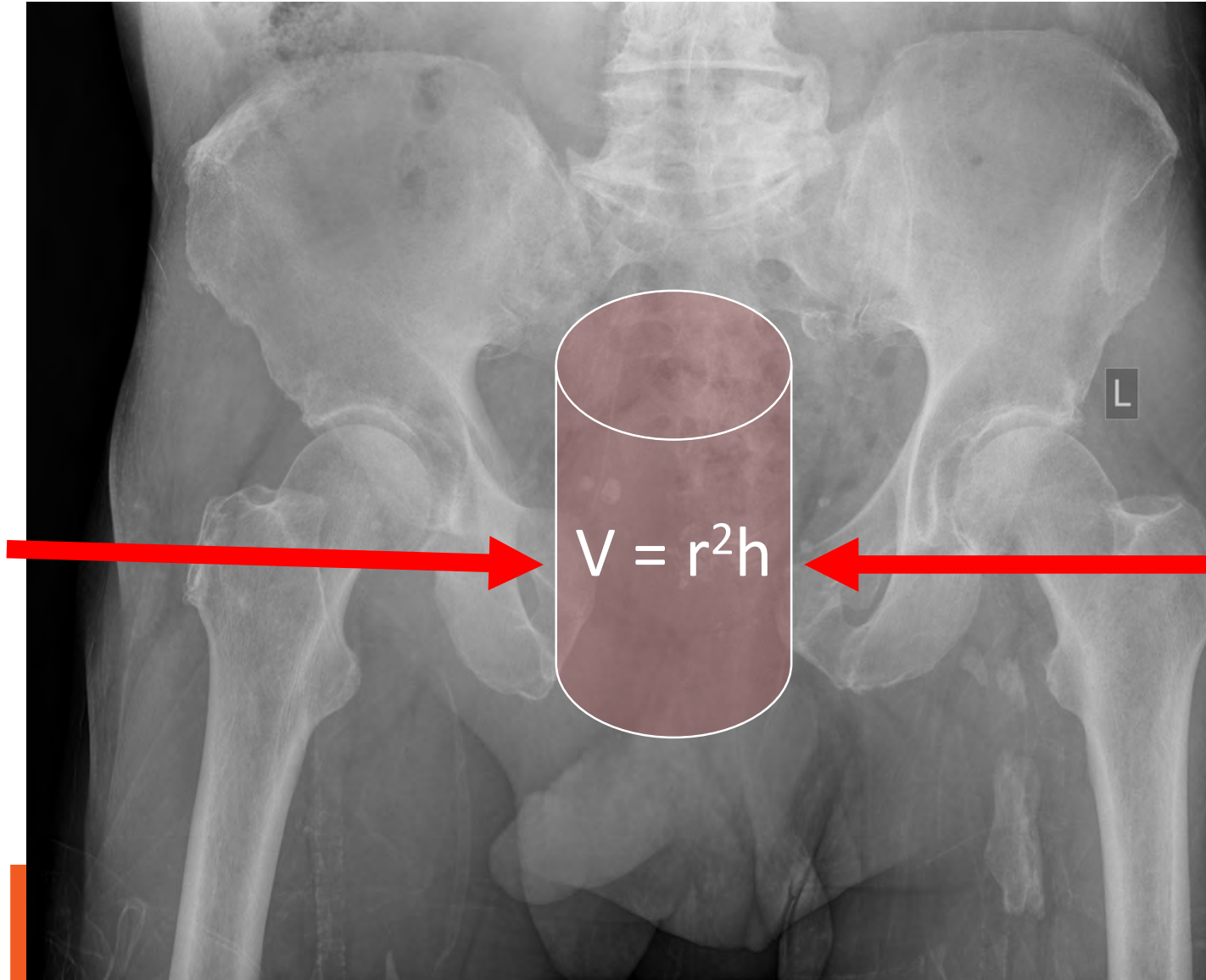
Volume Expanding



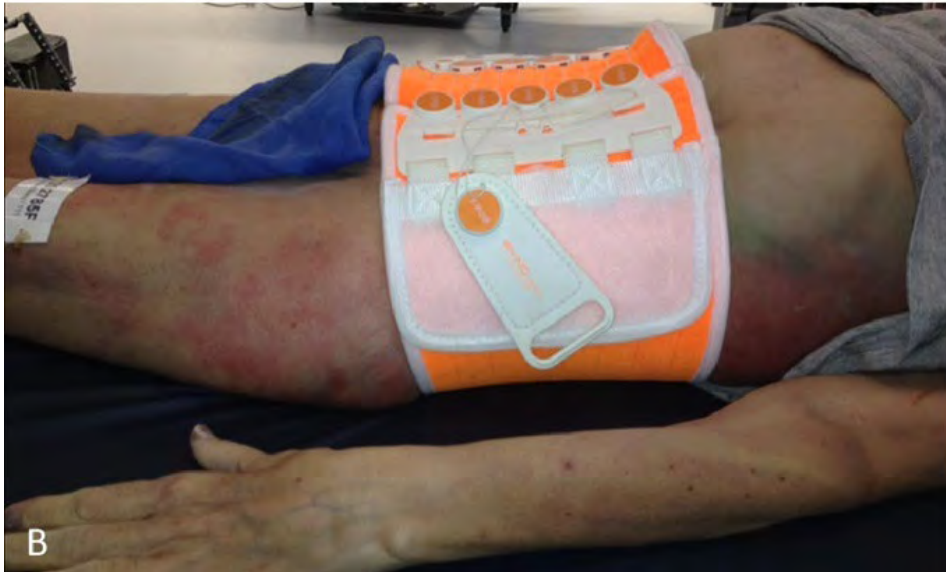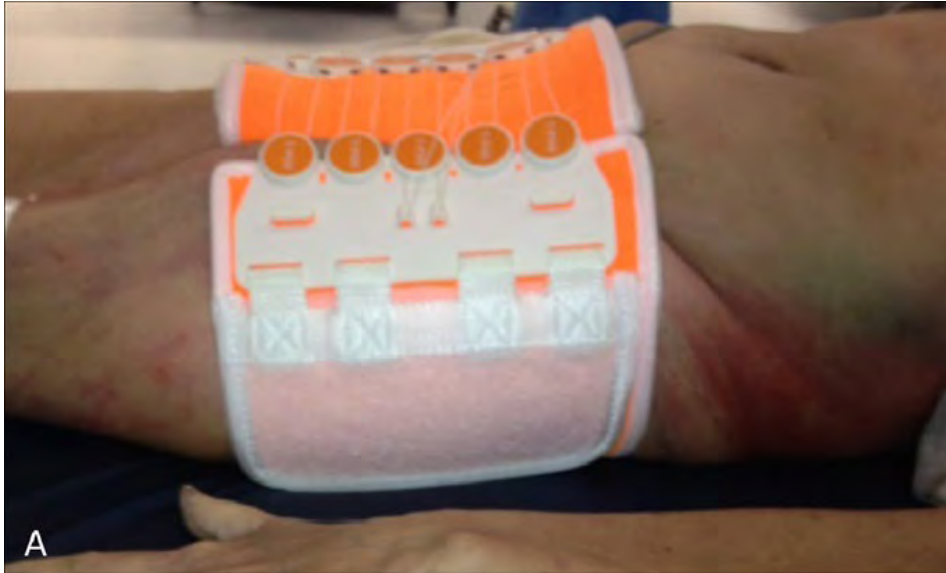“Open book”
“APC”

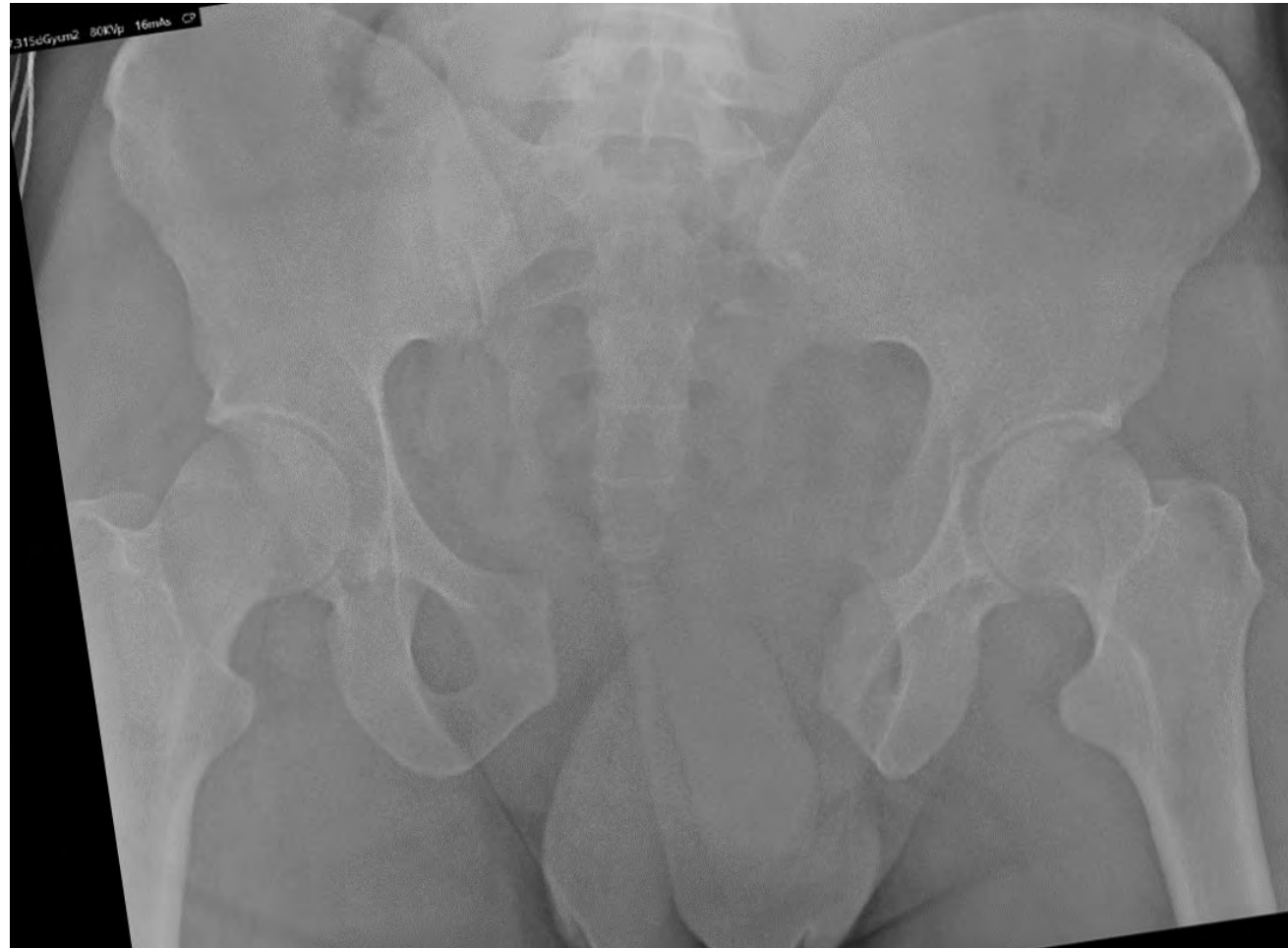

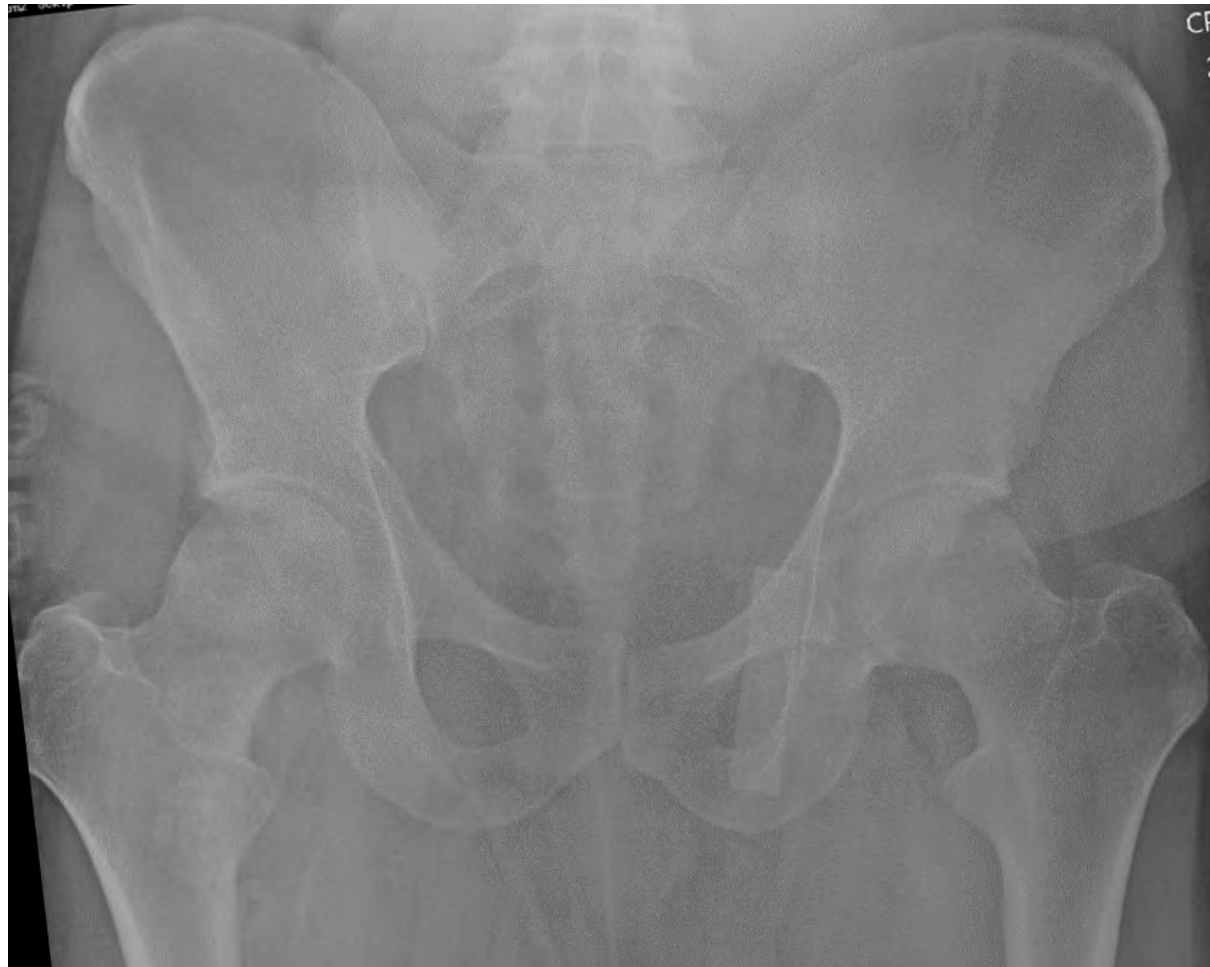Volume Expanding



“Open book”
“APC”



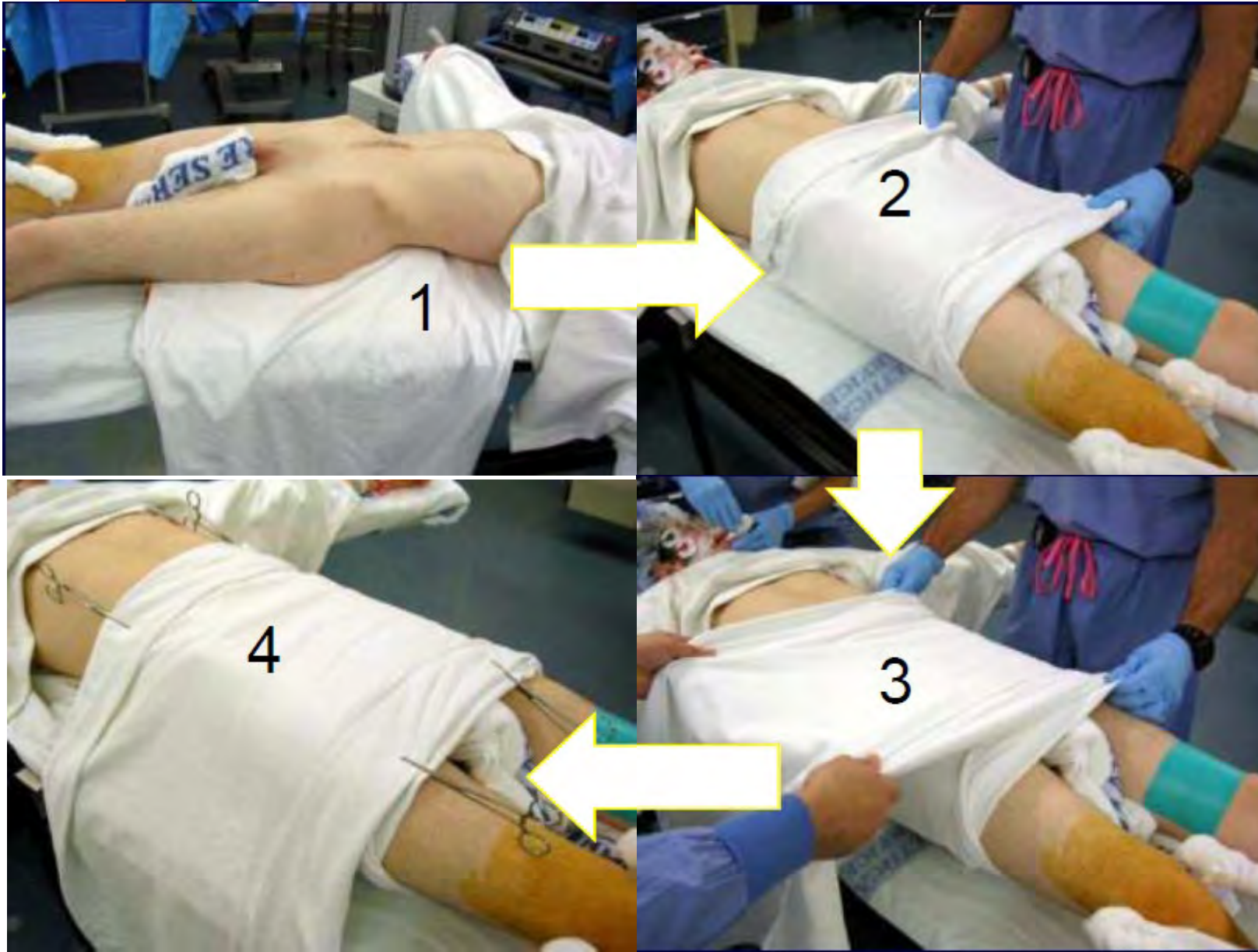






Alternatives?

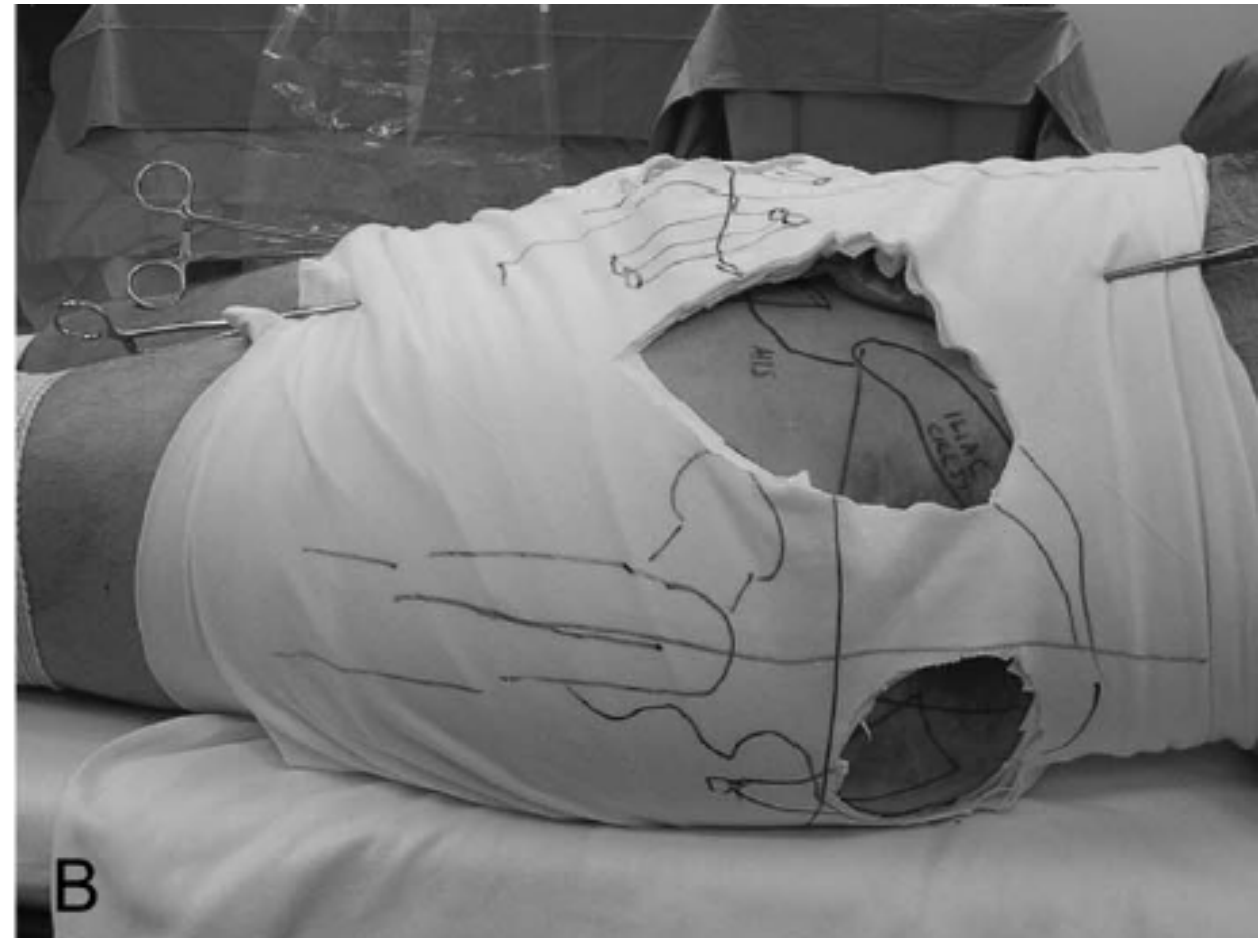
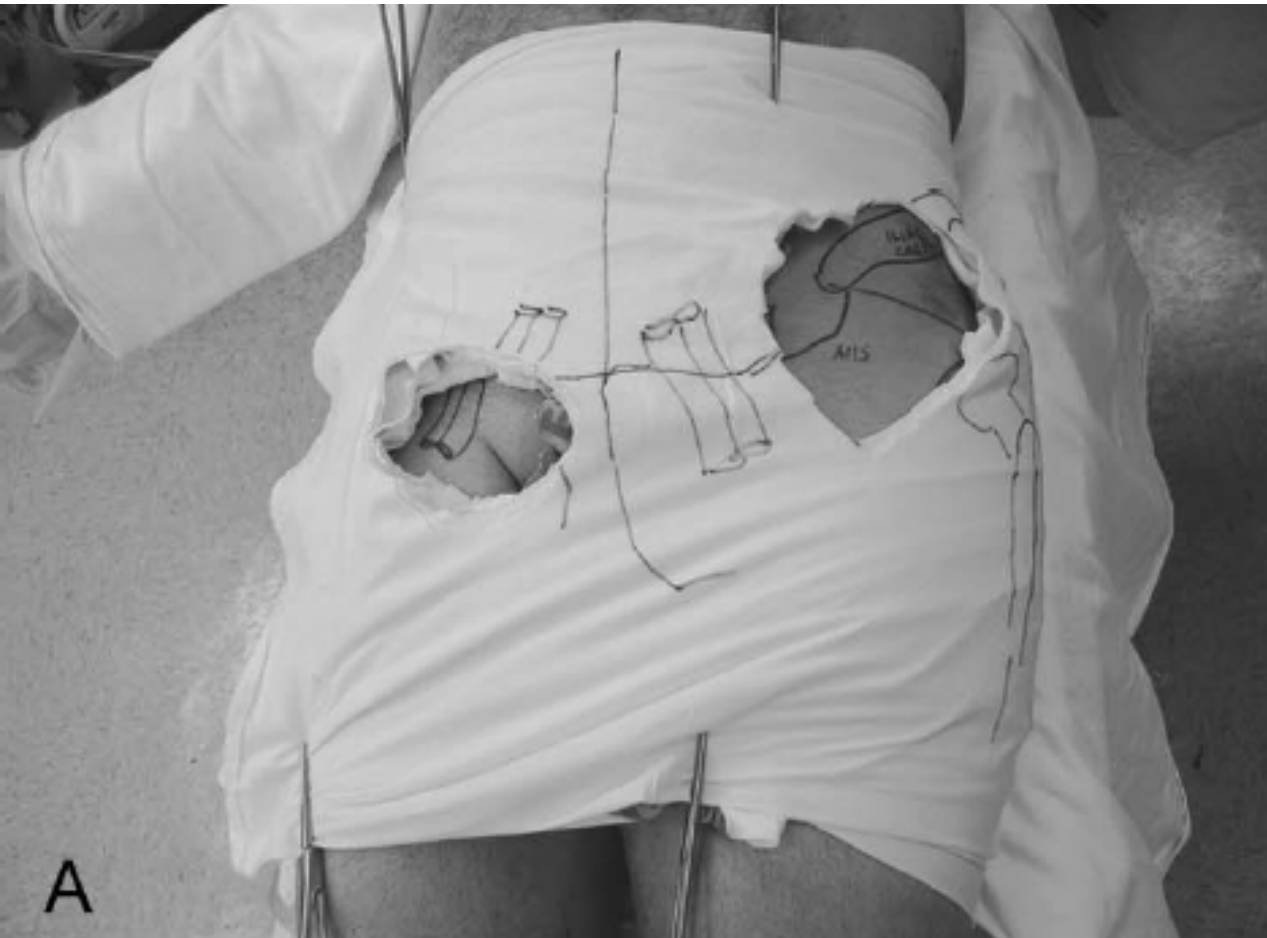




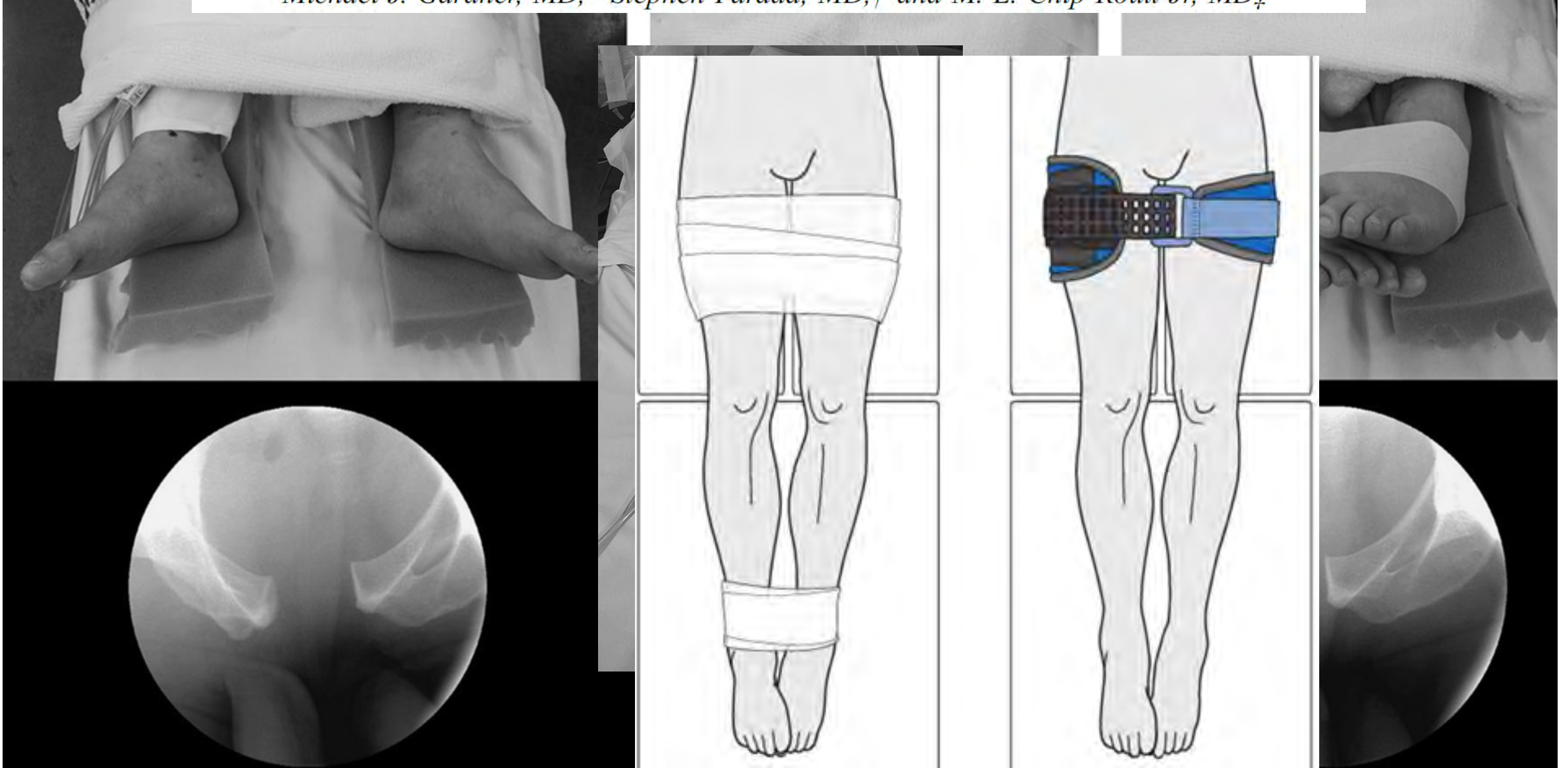
Percutaneous Pelvic Fixation Using Working Portals in a Circumferential Pelvic Antishock Sheet

Michael J. Gardner, MD, Greg Osgood, MD,† Robert Molnar, MD,‡
and Milton L. Chip Routt, Jr, MD§*



Internal Rotation and Taping of the Lower Extremities for Closed Pelvic Reduction

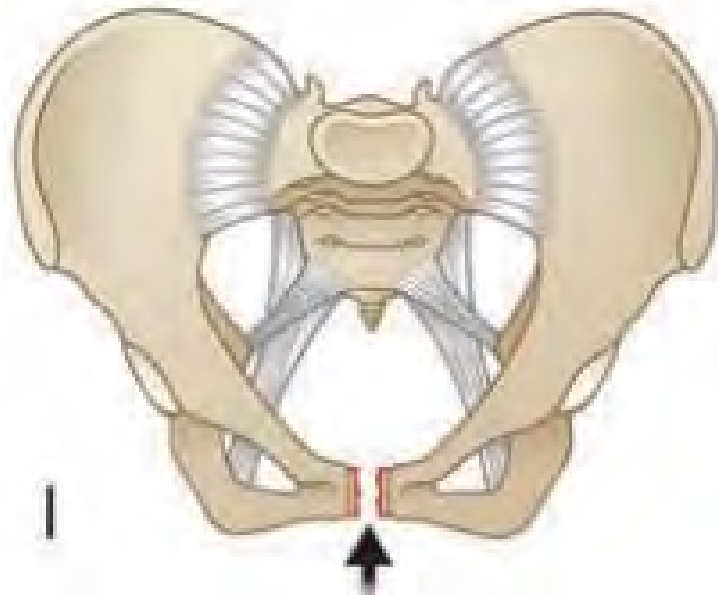
Michael J. Gardner, MD, Stephen Parada, MD,† and M. L. Chip Routt Jr, MD‡*



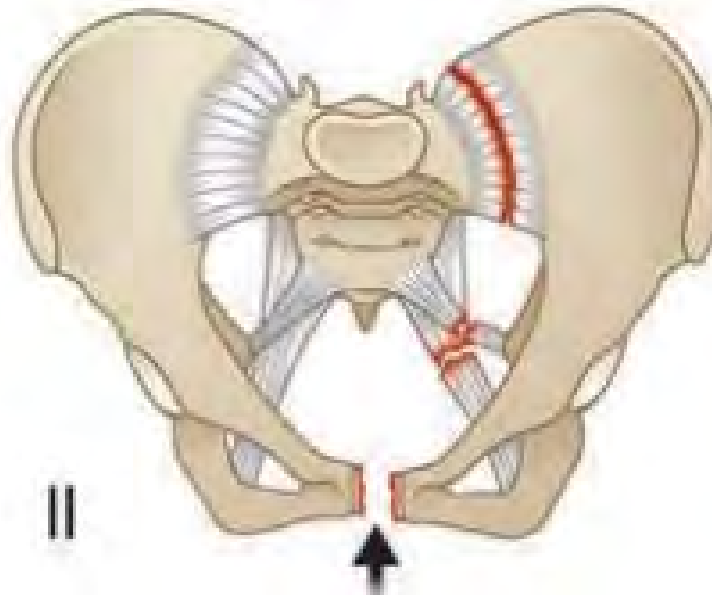


When to use?

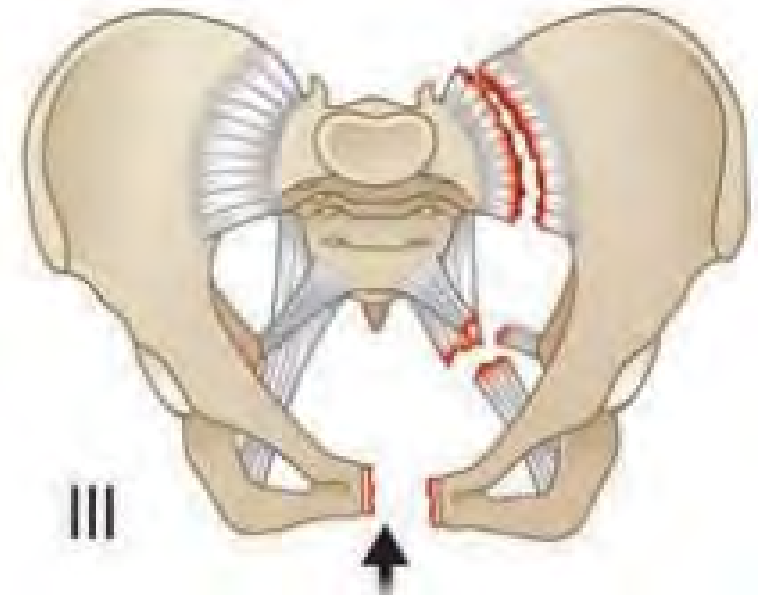
Anterior Posterior Compression (APC)



<2.5cm

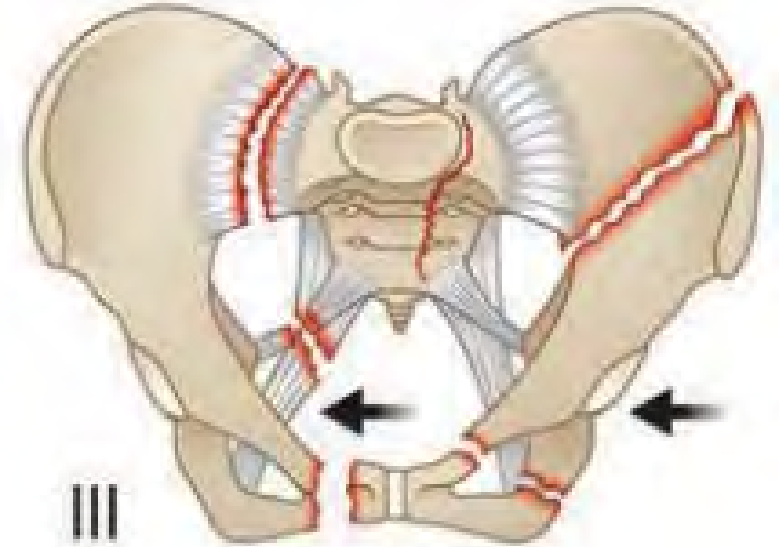
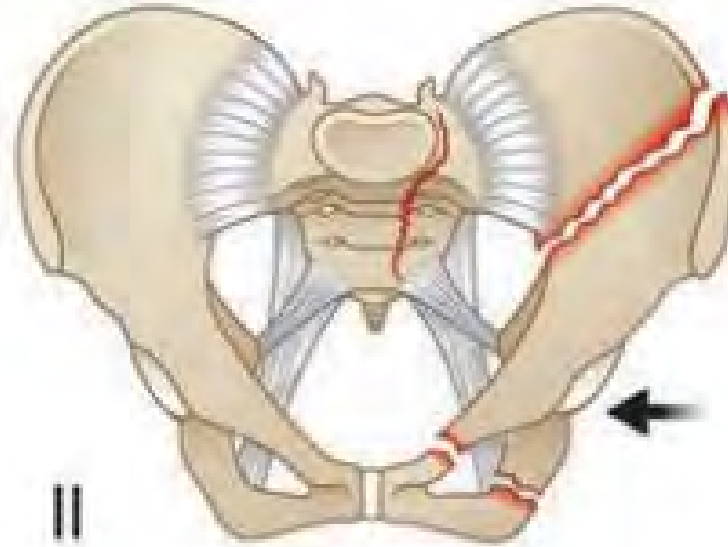
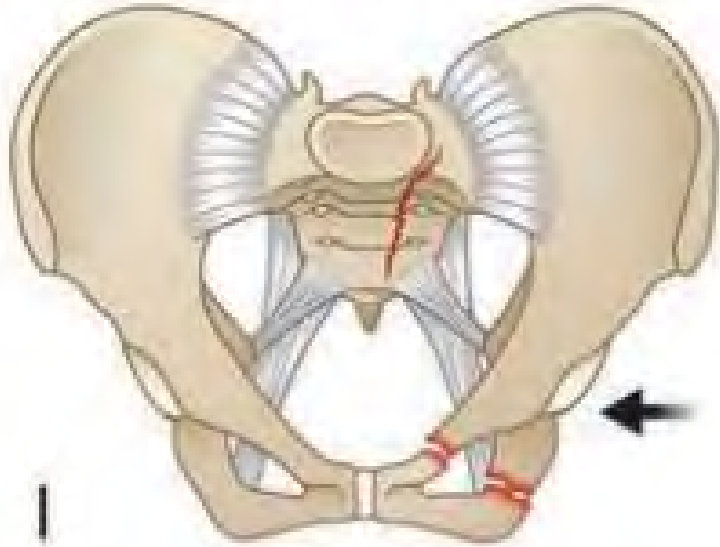


>2.5cm



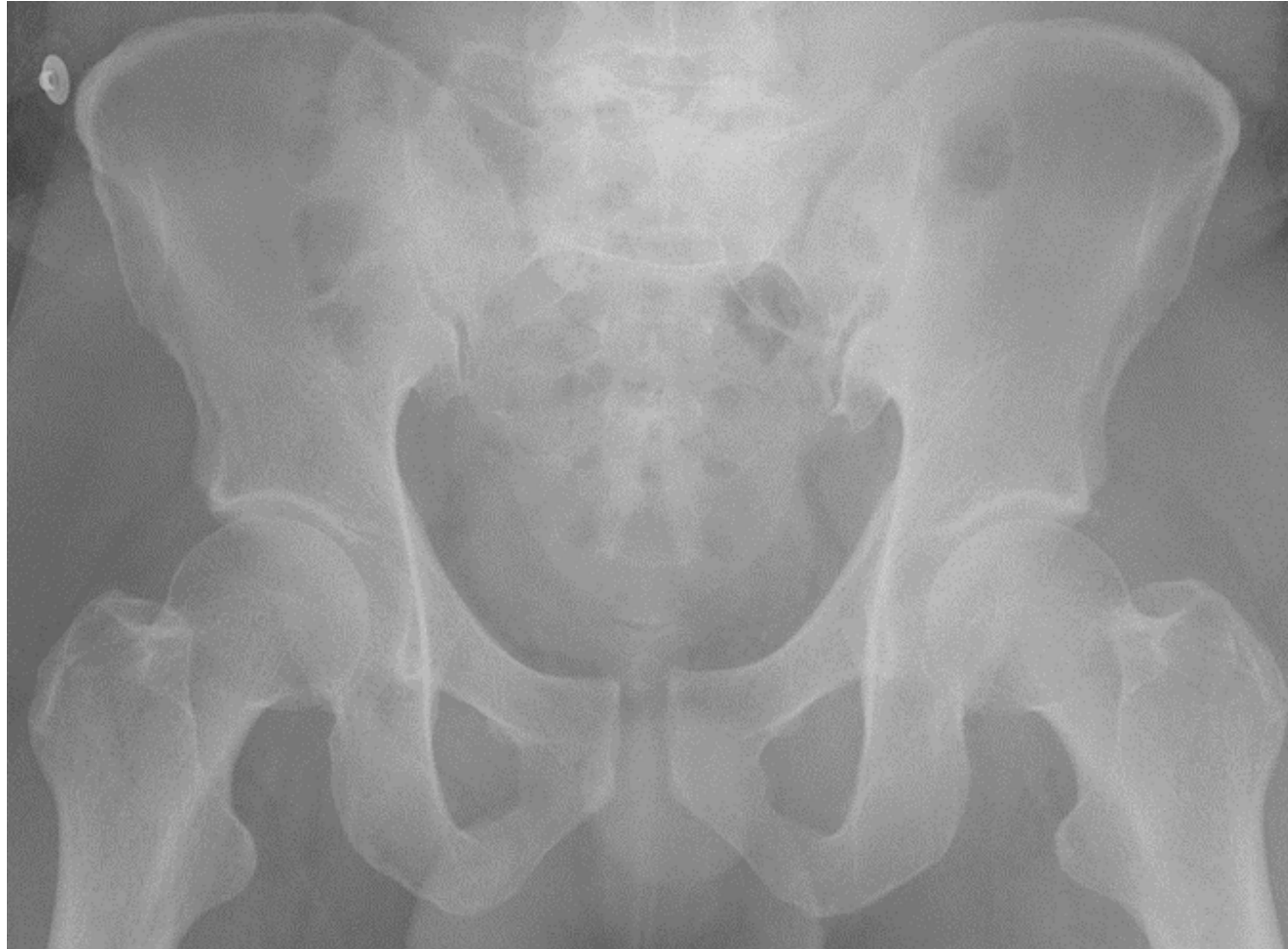


Lateral Compression (LC)

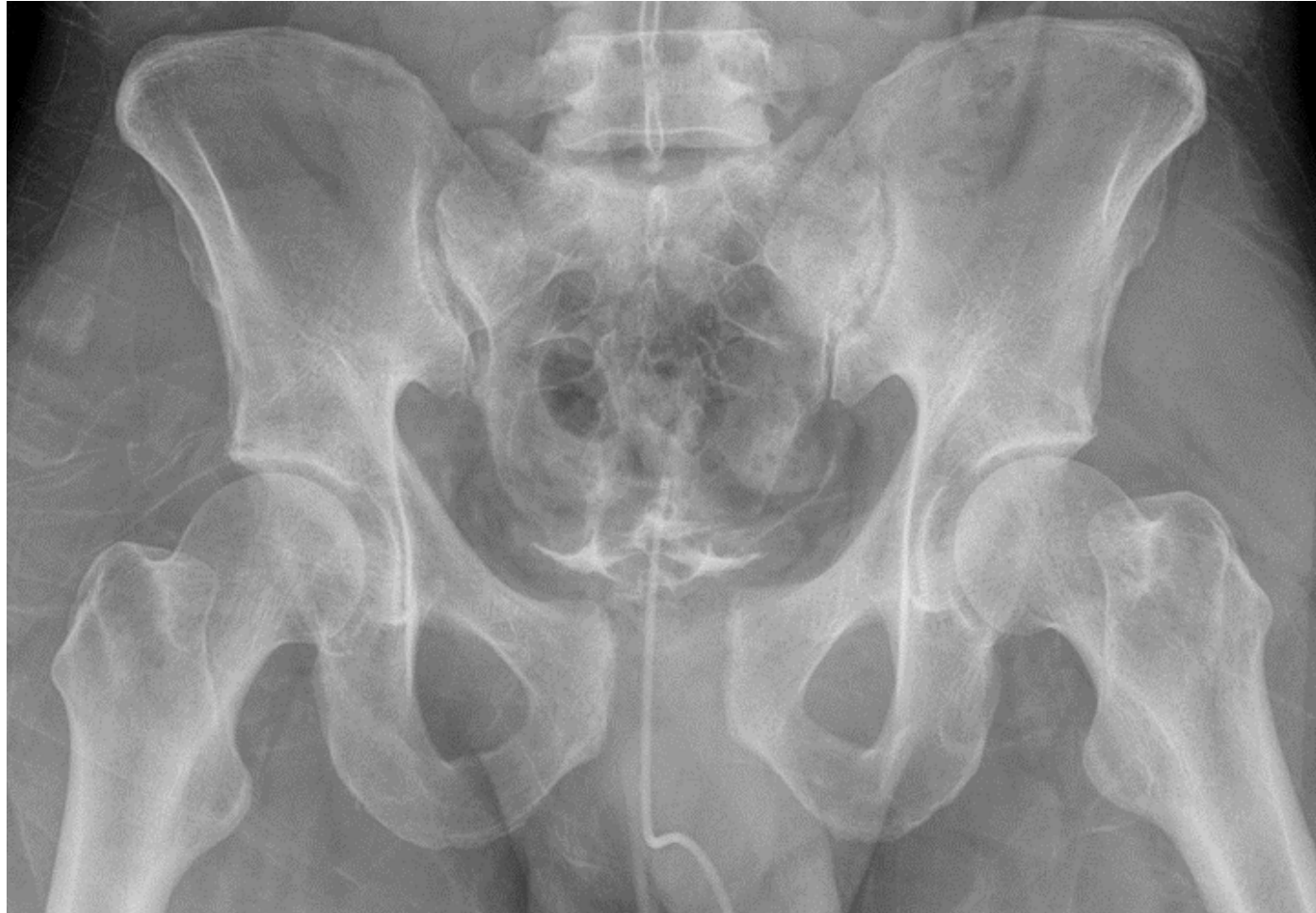



1-2 cm? (APC 1)



>2cm? (APC 2)





Stable?

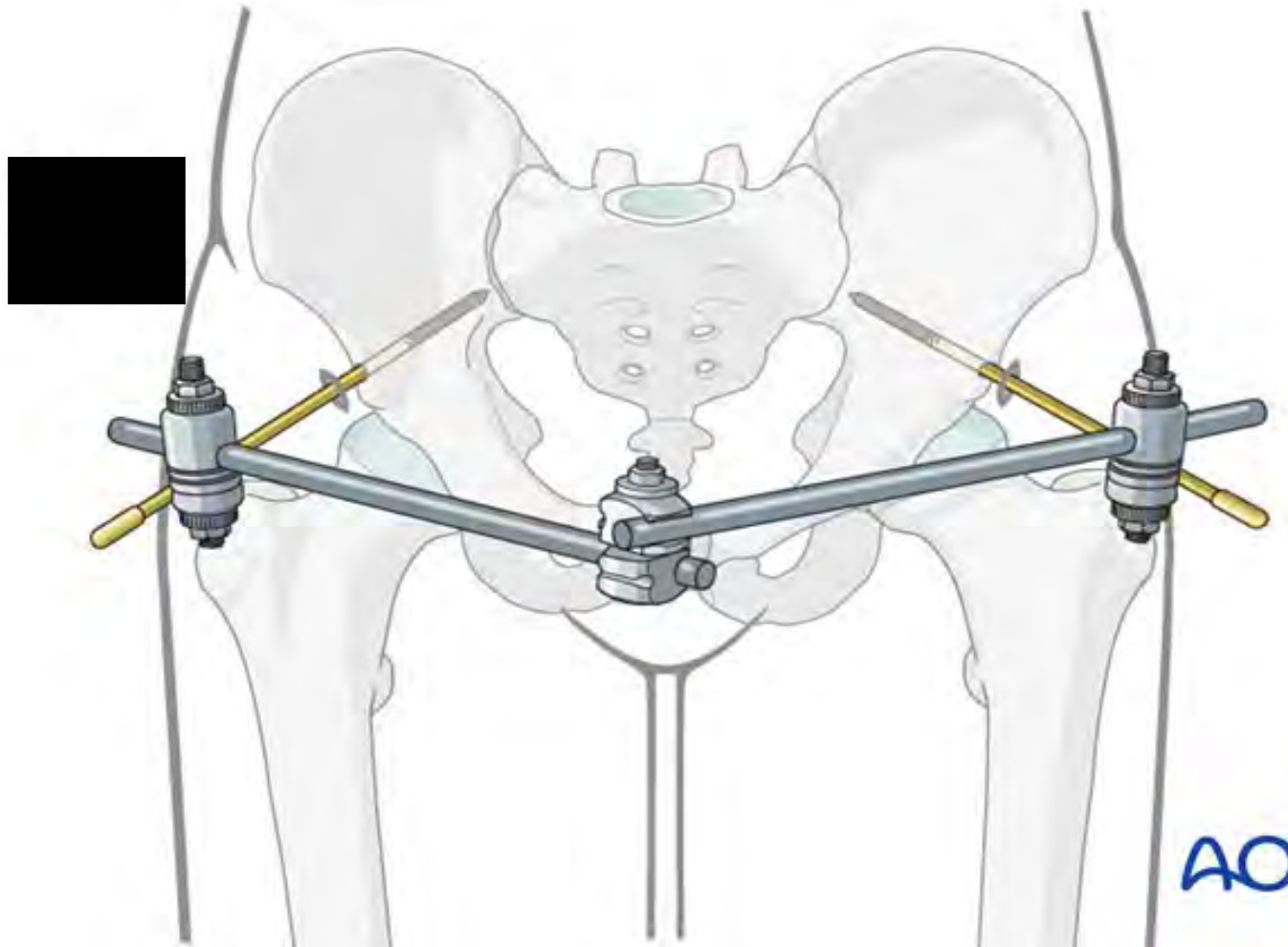
ORIF

IR embolization
External fixator
Pelvic packing



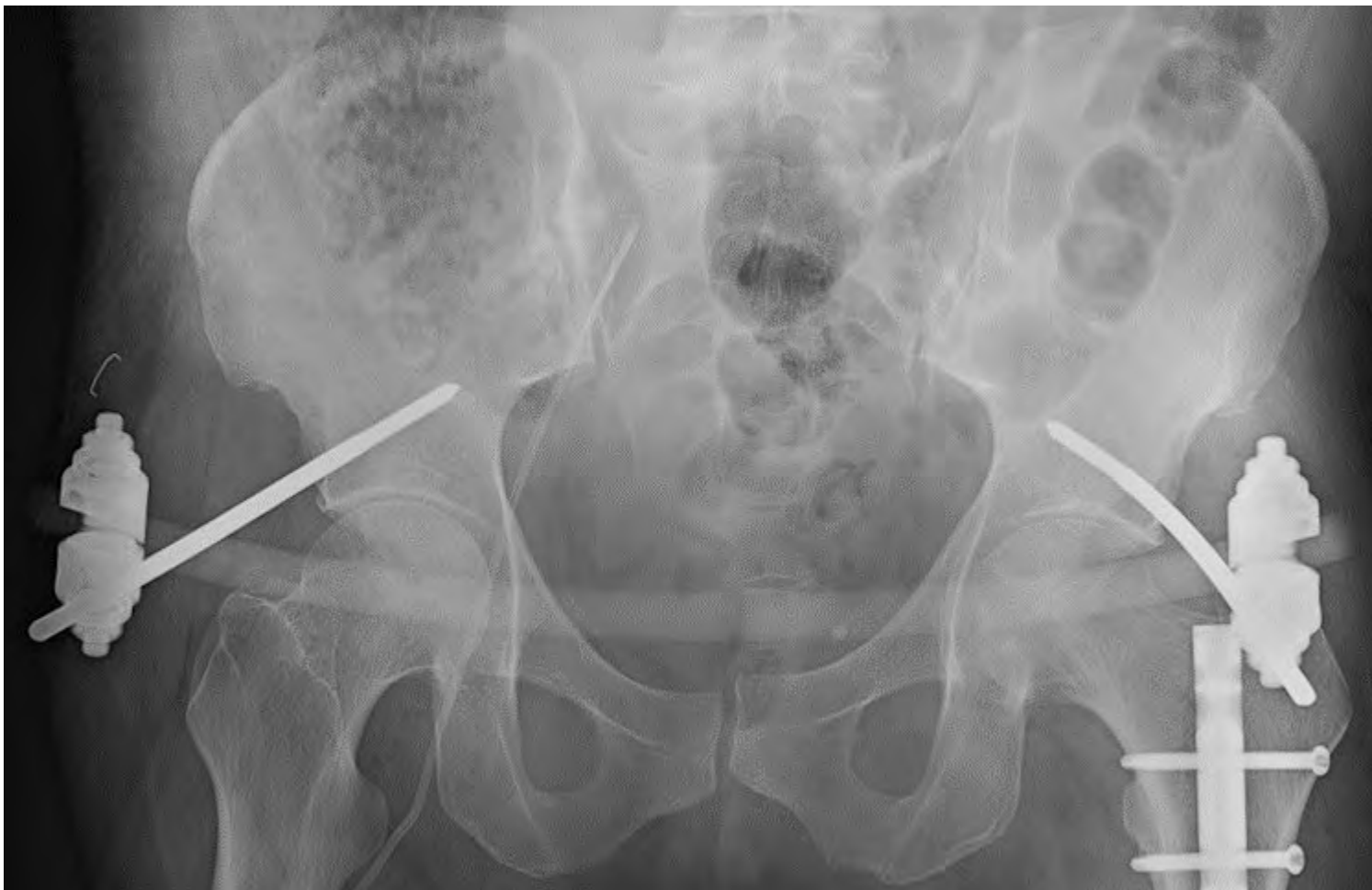


External fixator (ex-fix) in OR





10 minutes later



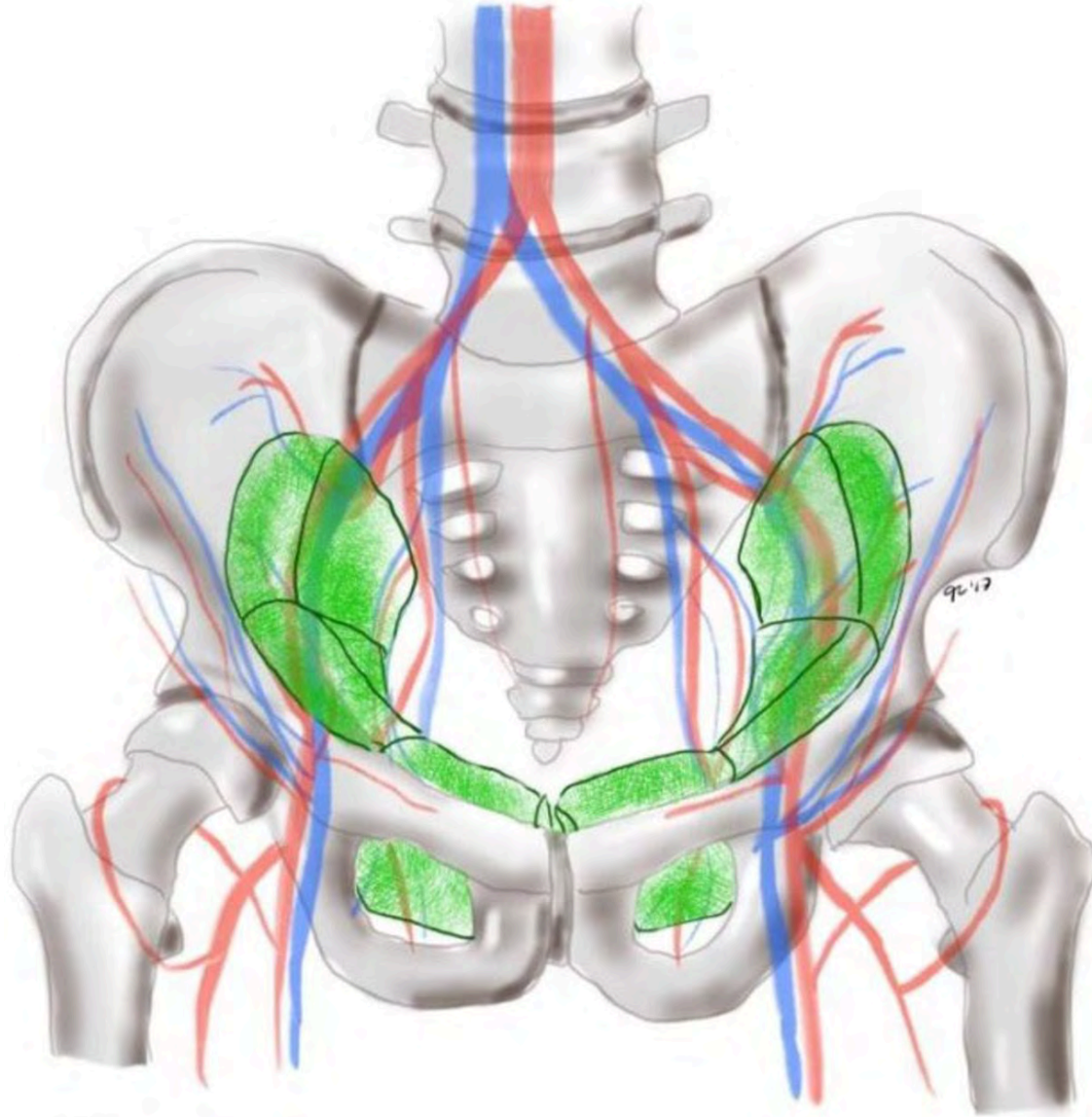


Still hypotensive?

- Pelvic packing
 - After mechanical stability!
 - ↑ infection risk?



Packing





Genitourinary

- Bladder or urethral injury in up to 29%





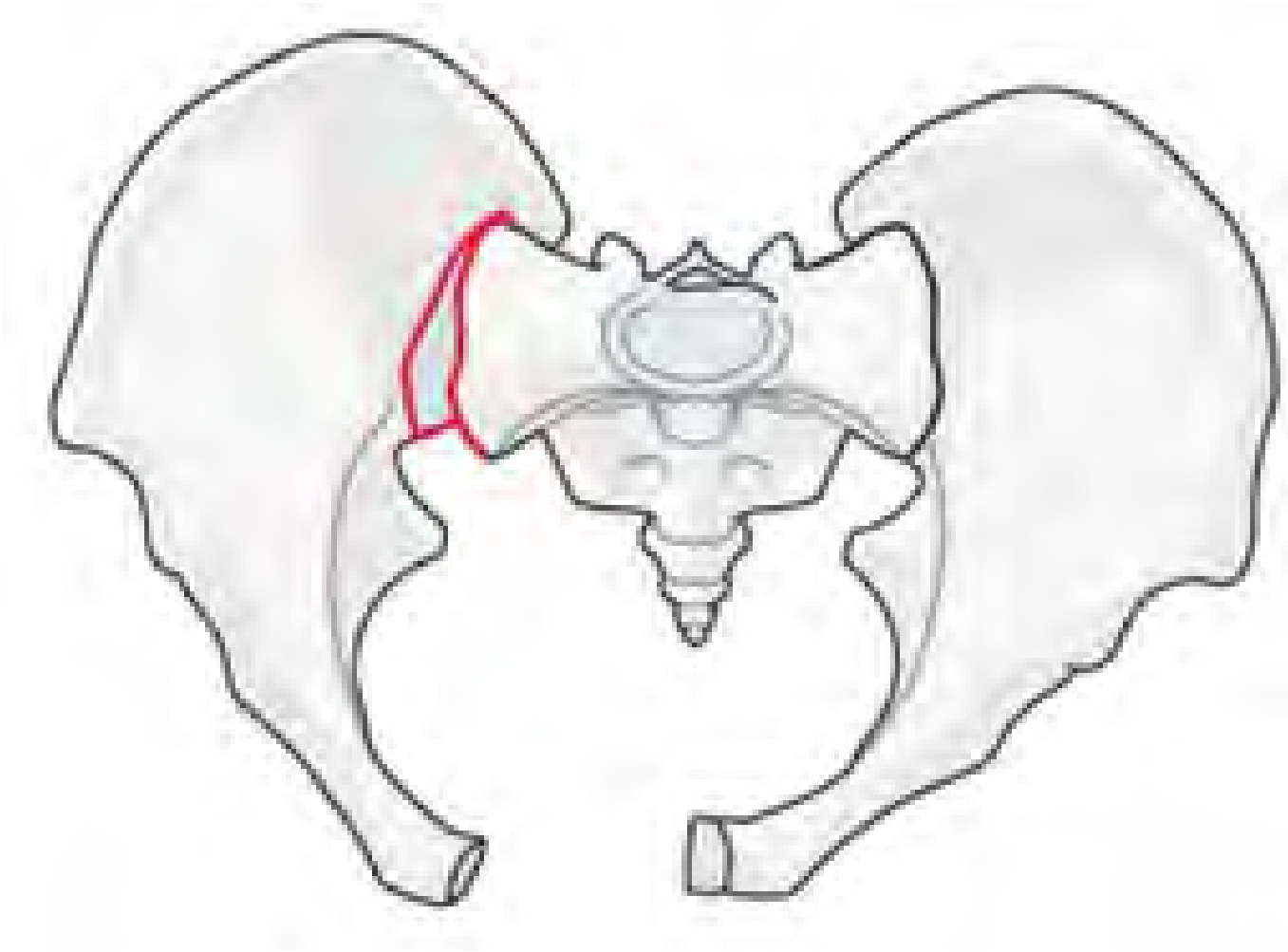
Foley

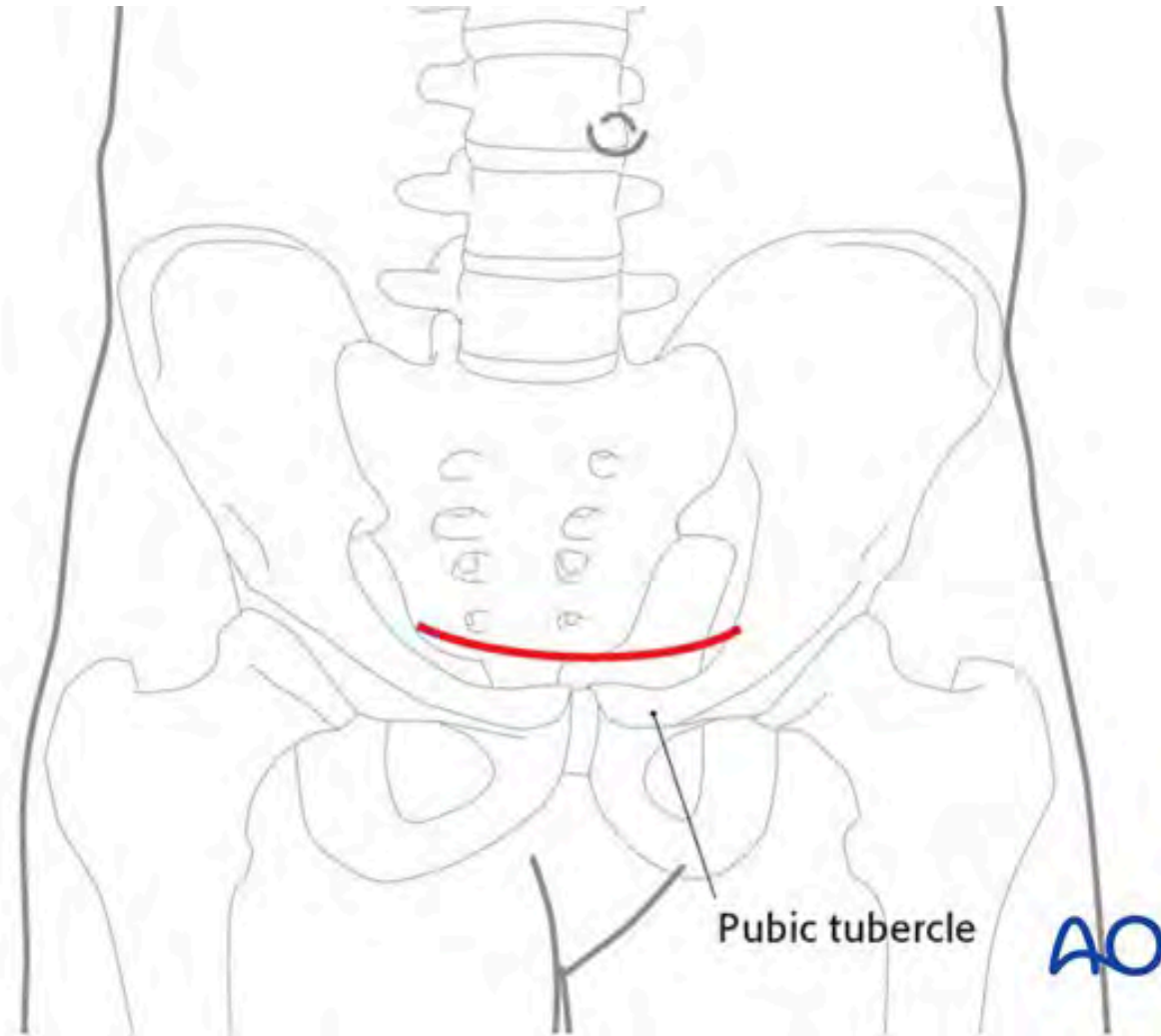
- UA
- Advanced imaging
 - Retrograde urethrogram (RUG)
 - CT cystogram

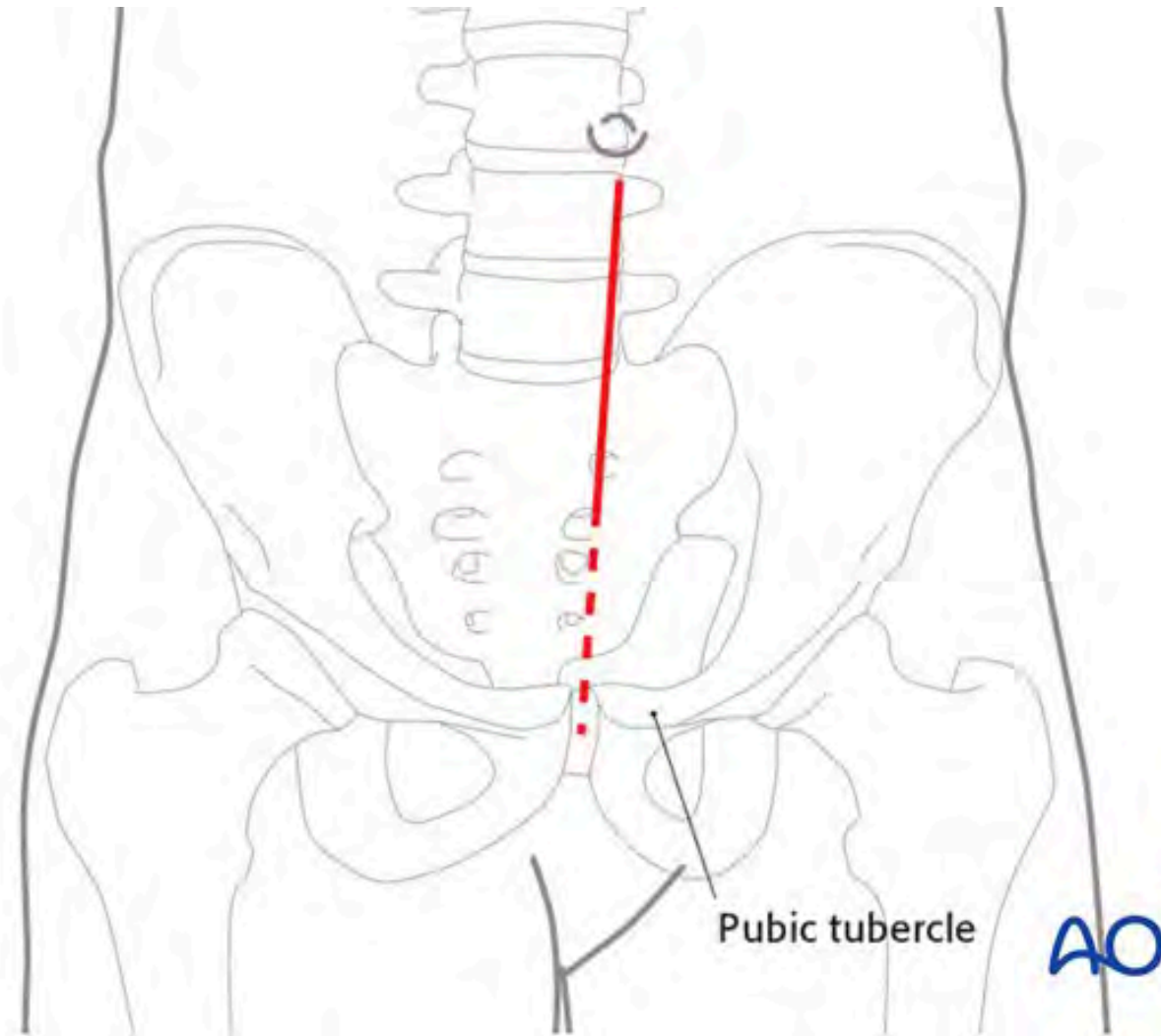


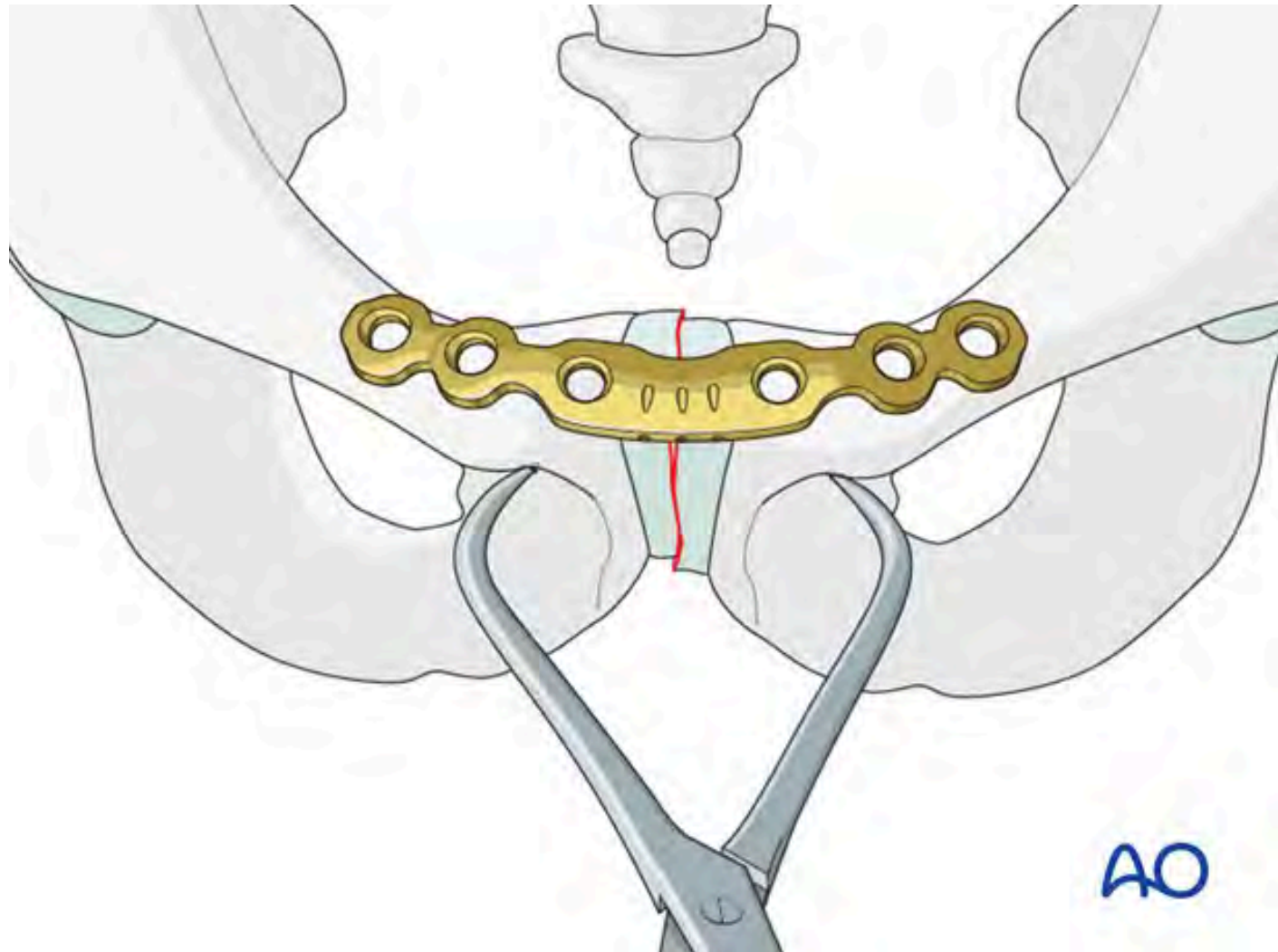


Definitive



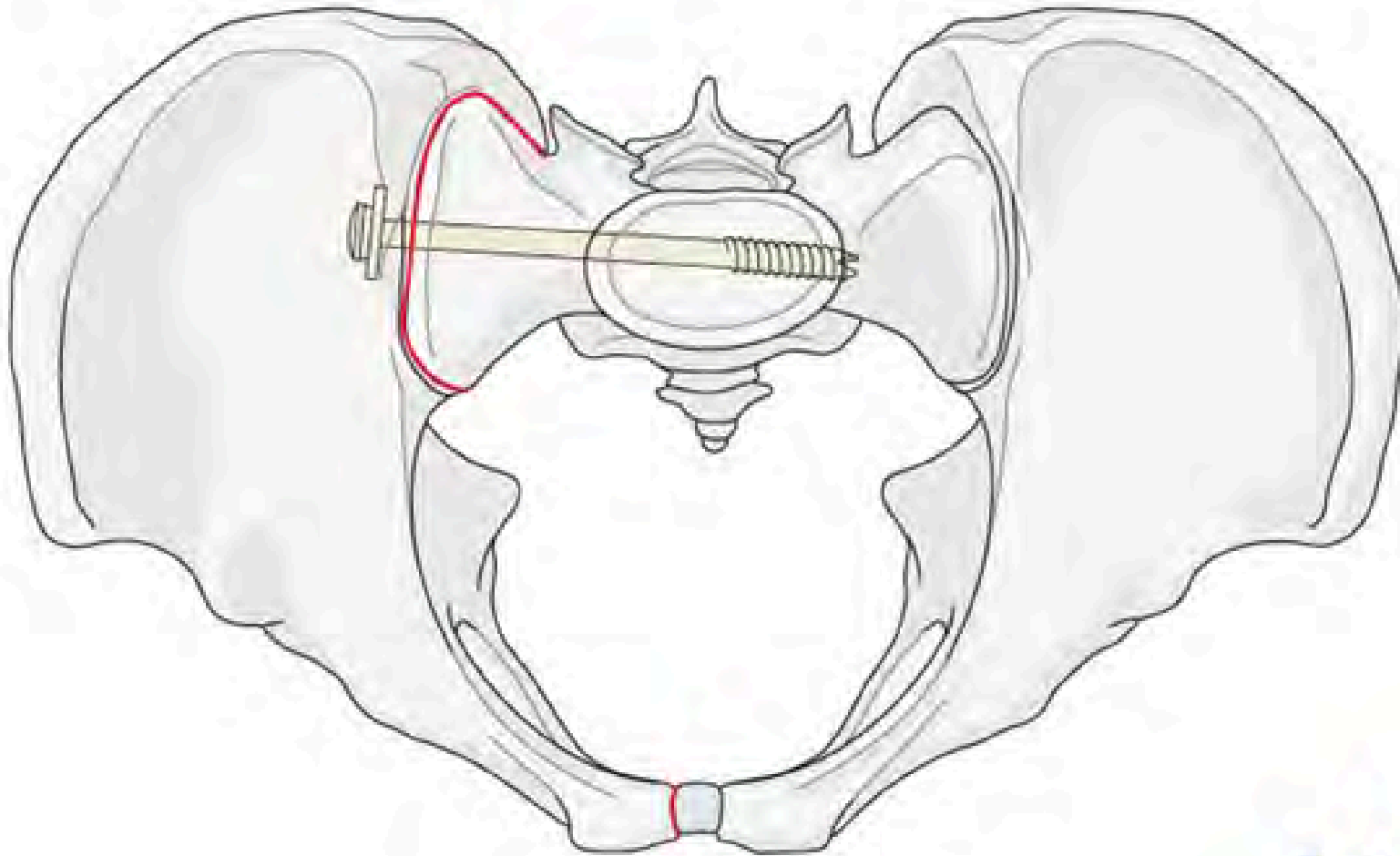






AO



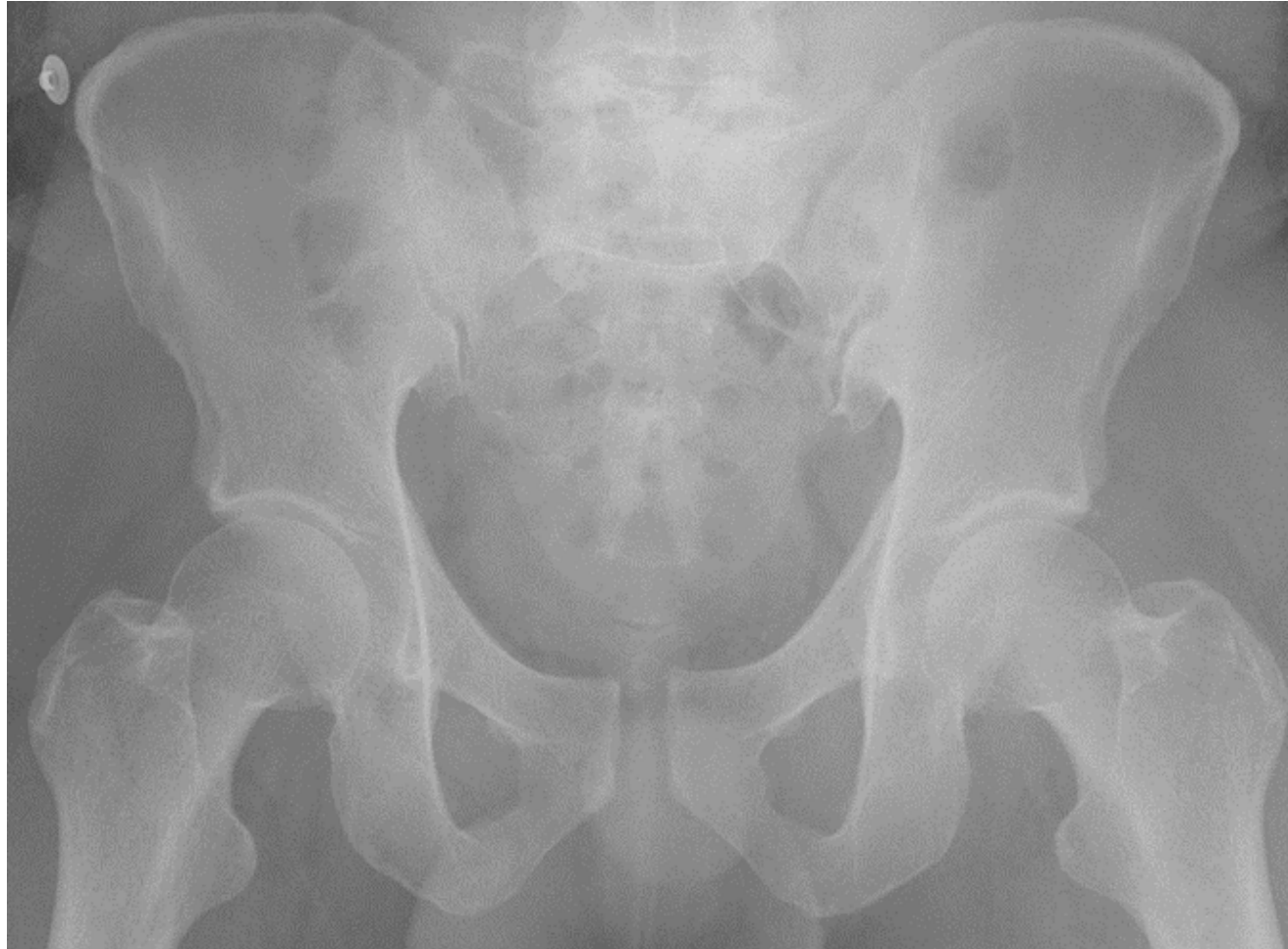


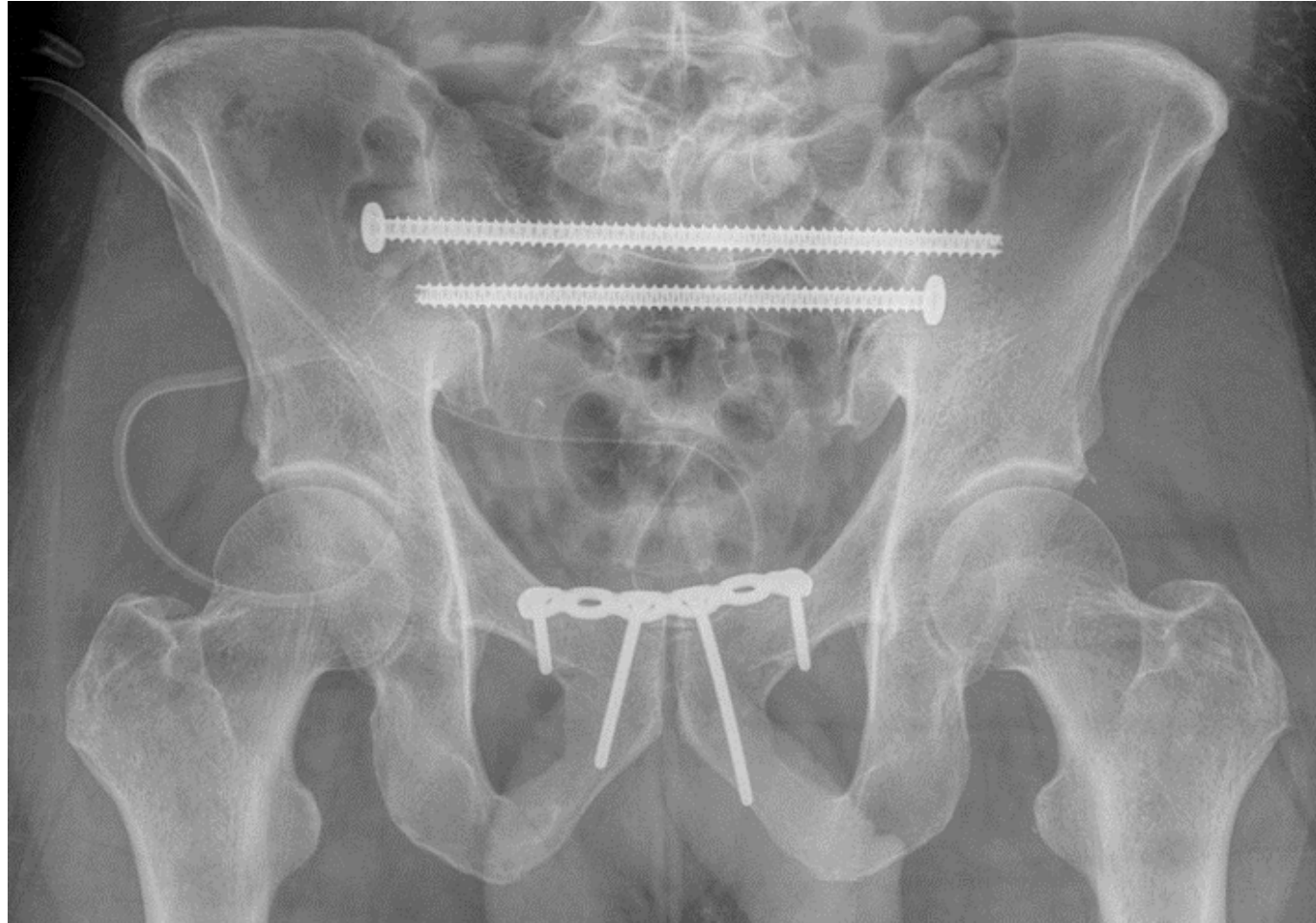
AO





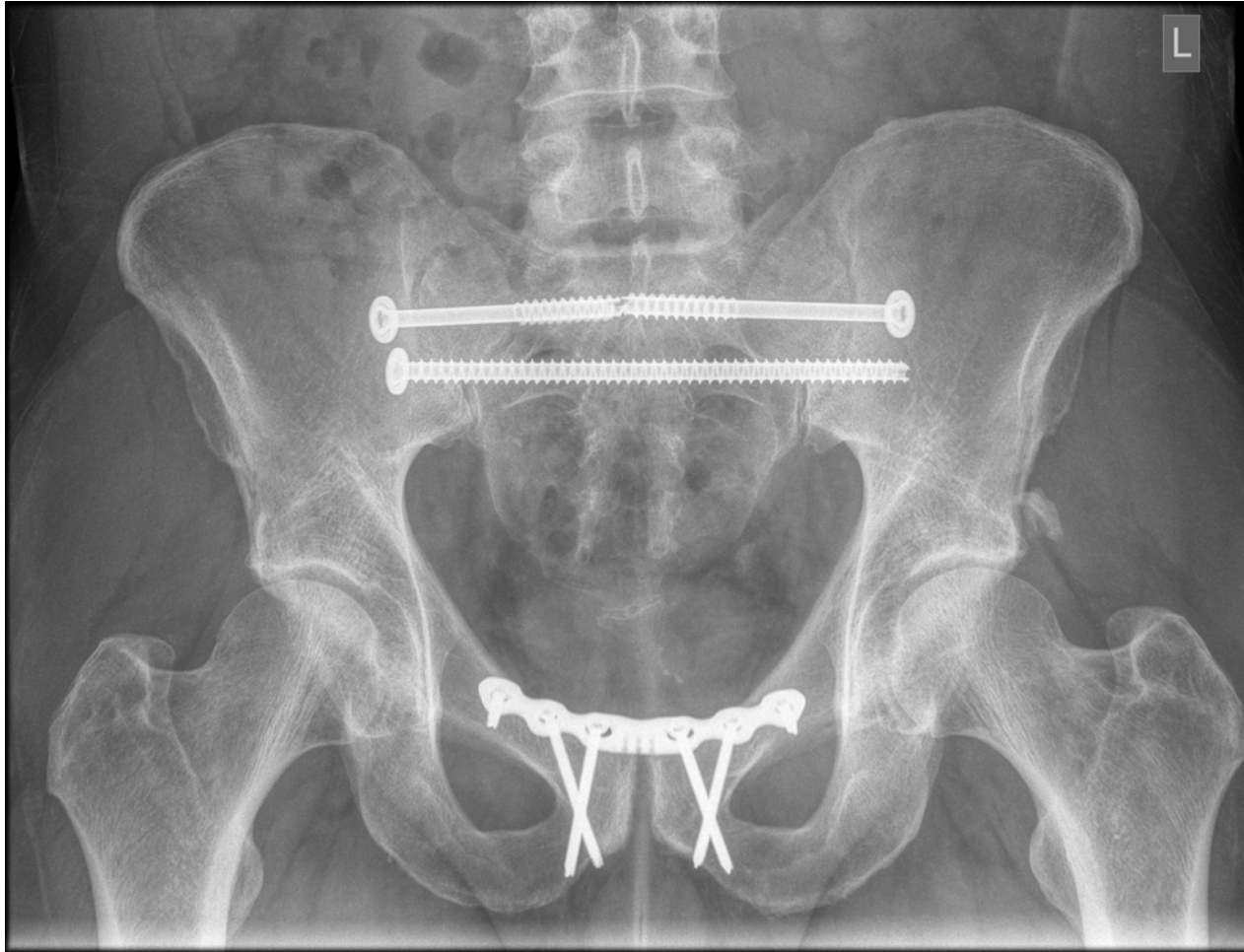
1-2 cm? (APC 1)

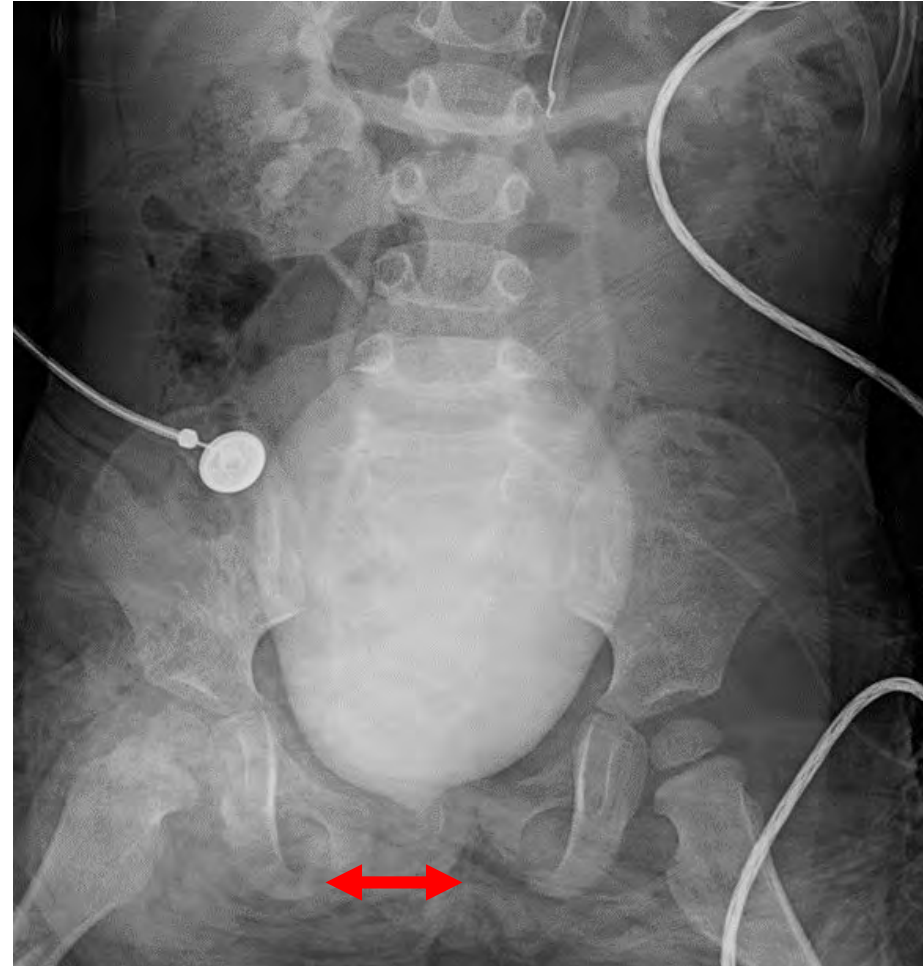


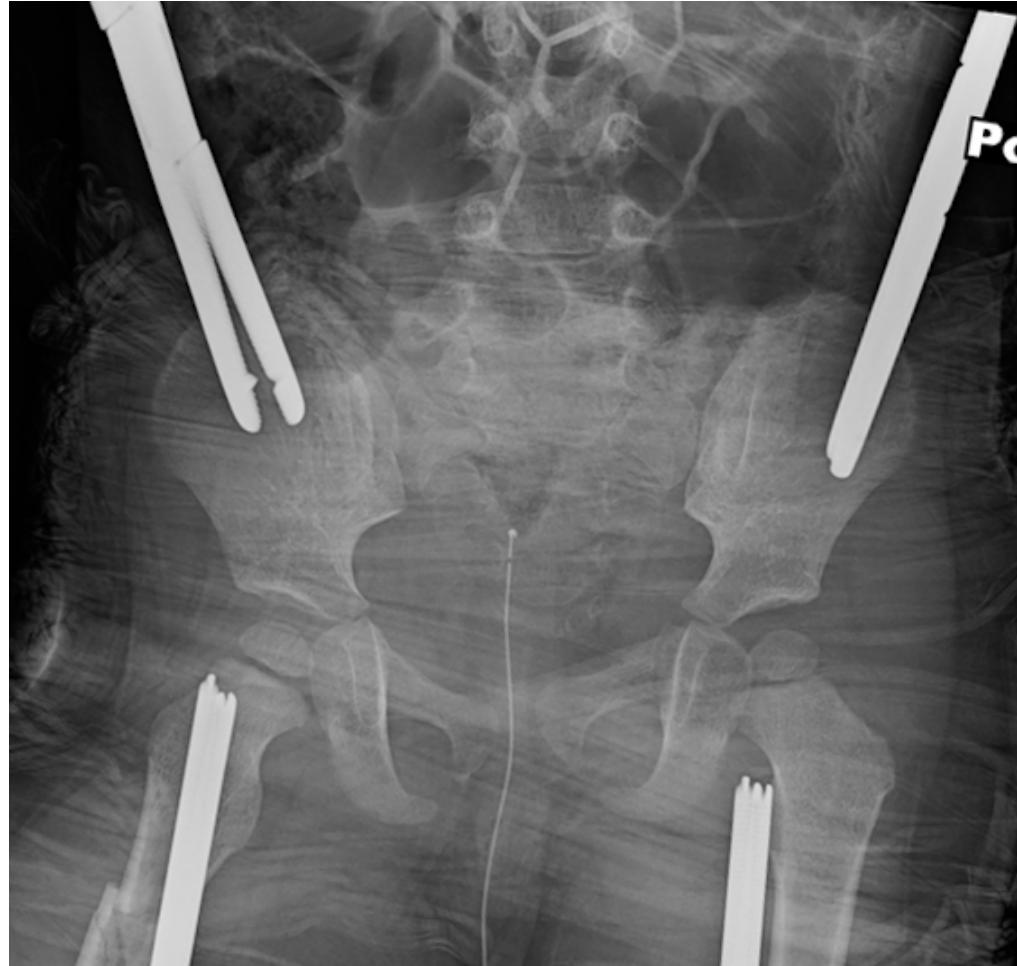
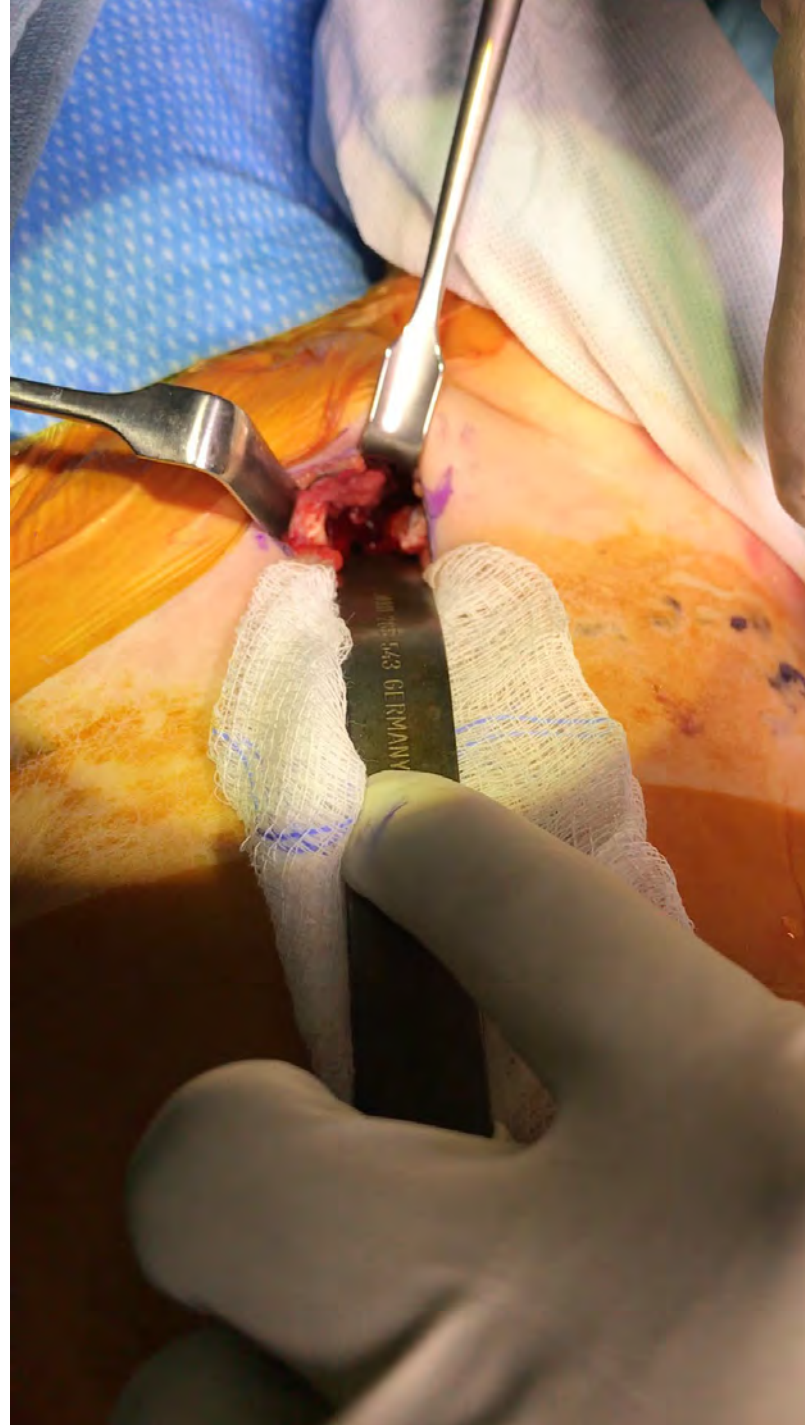>2cm? (APC 2)

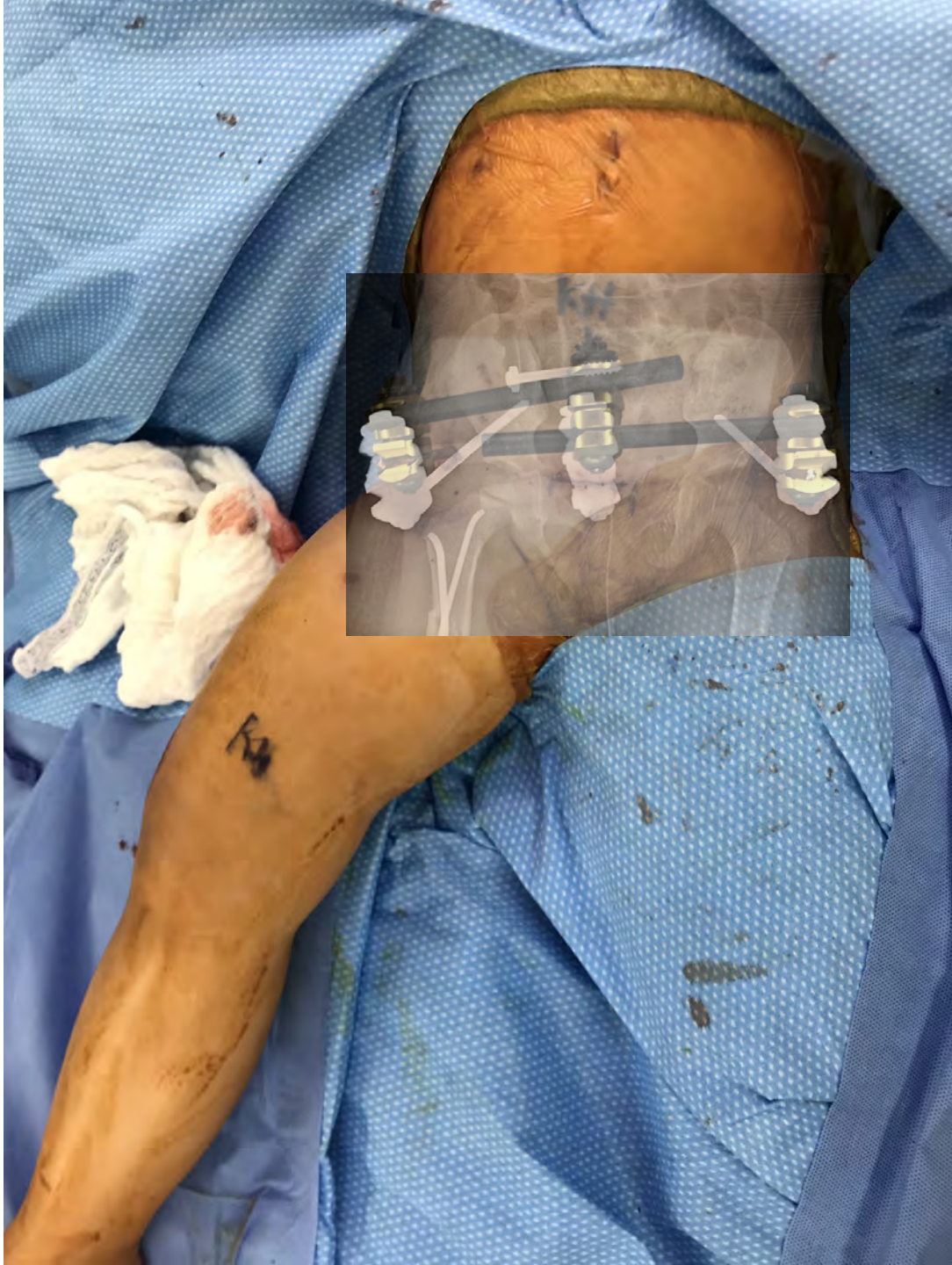

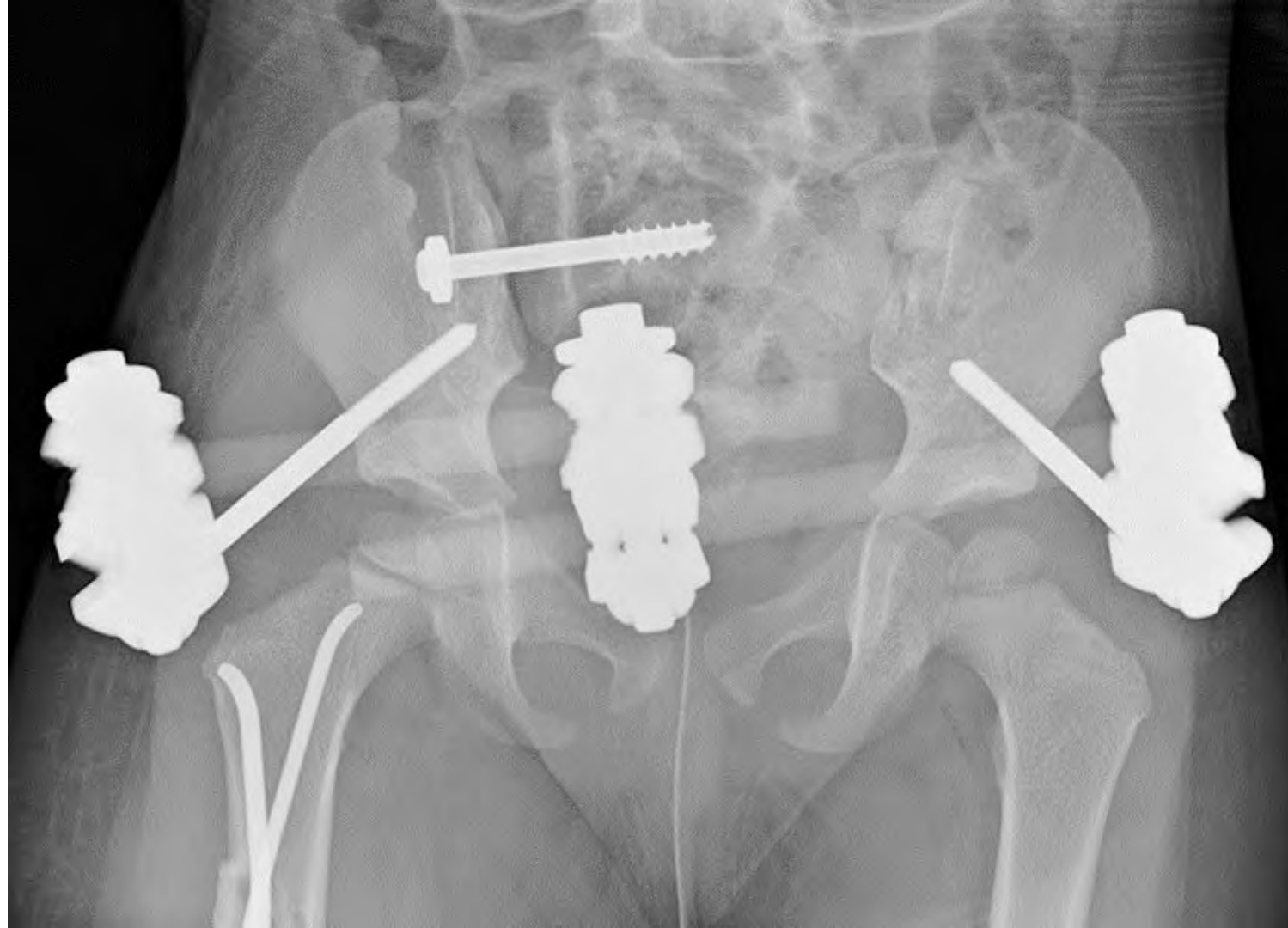

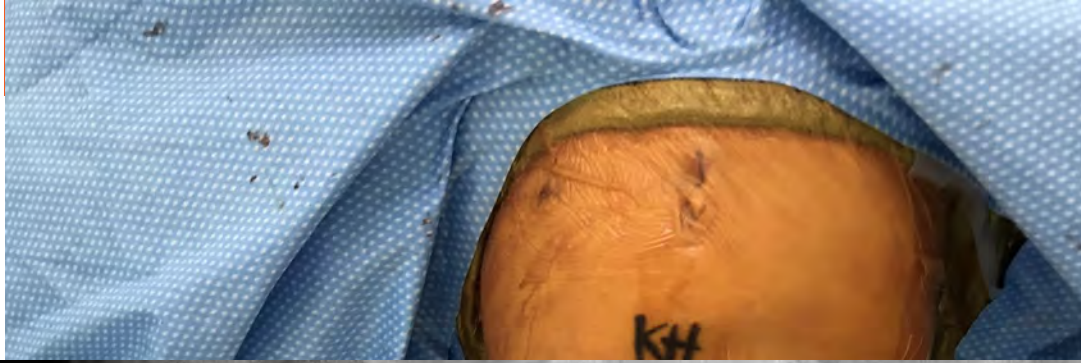












Questions?

